

Der Kreuzschmerz und seine Diagnose: wie spezifisch ist „unspezifisch“



Peter Machacek

Einführung

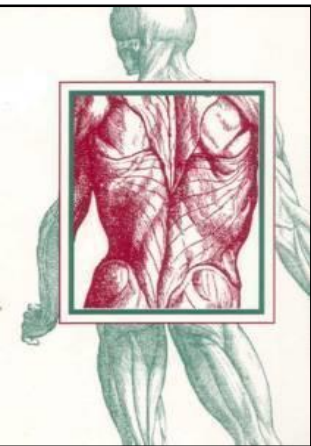
ISG

Facetten

Discus

Piriformis

Take Home



Kreuzschmerz (Low back Pain)

Einführung

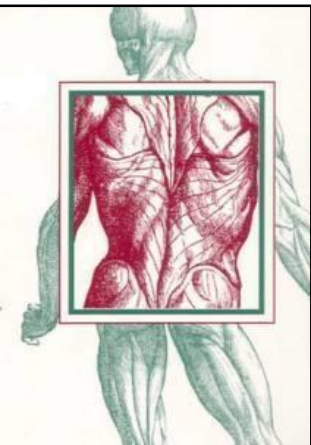
ISG

Facetten

Discus

Piriformis

Take Home



Kreuzschmerz (Low back Pain)



Indikation Wirbelsäulen OP



n = 183

Einführung

ISG

Facetten

Discus

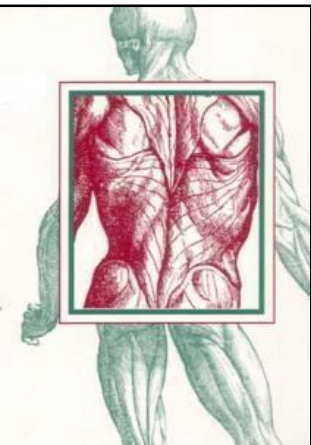
Piriformis

Take Home

[Surg Neurol. Int](#) 2013 Oct 29;4(Suppl 5):S353-8.

Are recommended spine operations either unnecessary or too complex? Evidence from second opinions

[Nancy E Epstein¹](#)



Kreuzschmerz (Low back Pain)



Indikation Wirbelsäulen OP



n = 183

second opinion:

Einführung

ISG

Facetten

Discus

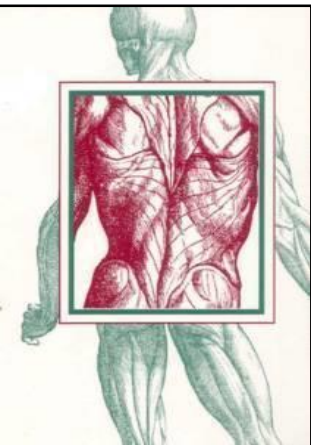
Piriformis

Take Home

[Surg Neurol. Int](#) 2013 Oct 29;4(Suppl 5):S353-8.

Are recommended spine operations either unnecessary or too complex? Evidence from second opinions

[Nancy E Epstein](#)¹



Kreuzschmerz (Low back Pain)



Indikation Wirbelsäulen OP



n = 183

second opinion:

- 60,7% „unnecessary“

Einführung

ISG

Facetten

Discus

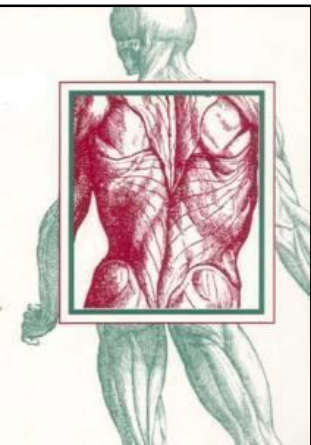
Piriformis

Take Home

[Surg Neurol. Int 2013 Oct 29;4\(Suppl 5\):S353-8.](#)

Are recommended spine operations either unnecessary or too complex? Evidence from second opinions

[Nancy E Epstein¹](#)



Kreuzschmerz (Low back Pain)



Indikation Wirbelsäulen OP



n = 183

second opinion:

- 60,7% „unnecessary“
- 33,3 % „wrong“

[Surg Neurol. Int 2013 Oct 29;4\(Suppl 5\):S353-8.](#)

Are recommended spine operations either unnecessary or too complex? Evidence from second opinions

[Nancy E Epstein¹](#)

Einführung

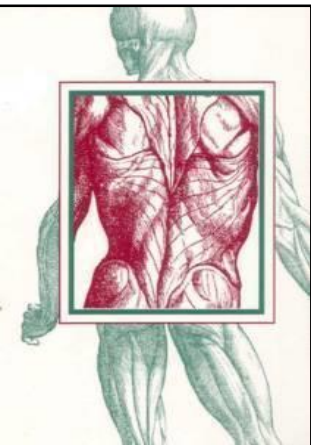
ISG

Facetten

Discus

Piriformis

Take Home



Kreuzschmerz (Low back Pain)



Indikation Wirbelsäulen OP



n = 183

second opinion:

- 60,7% „unnecessary“
- 33,3 % „wrong“
- 6% „right“

Surg Neurol. Int 2013 Oct 29;4(Suppl 5):S353-8.

Are recommended spine operations either unnecessary or too complex? Evidence from second opinions

[Nancy E Epstein¹](#)

Einführung

ISG

Facetten

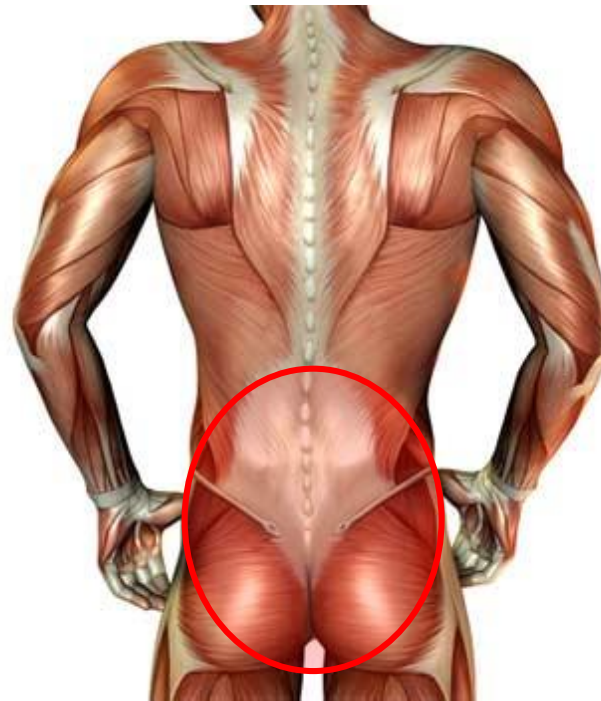Discus

Piriformis

Take Home

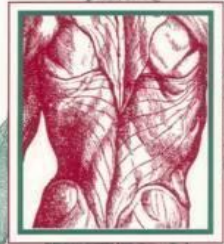Kreuzschmerz (Low back Pain)

Definition: Schmerzen im Bereich zwischen den **12. Rippen** und den unteren **Glutealfalten**



The Back Pain Revolution (1998)

[Gordon Waddell](#)



Einführung

ISG

Facetten

Discus

Piriformis

Take Home

Kreuzschmerz (Low back Pain)

spezifisch:



unspezifisch

Neoplasmen
Entzündungen
Infektionen
Verletzungen
Metabolische Erkrankungen
Psychische Erkrankungen
Nervenwurzelirritationen
Cauda equina Syndrom
Degenerative Erkrankungen



80 - 85 %

Einführung

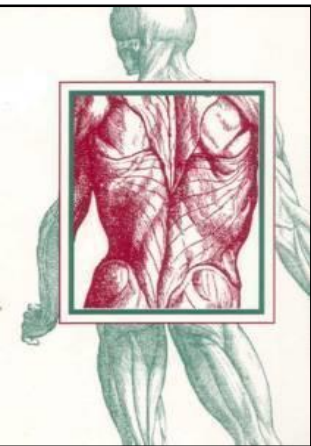
ISG

Facetten

Discus

Piriformis

Take Home



Kreuzschmerz (Low back Pain)



unspezifisch



80 - 85 %

[Br Med J.](#) (1966) Jul 9;2(5505):82-4.
Acute back syndrome-a study from general practice.
[Dillane JB](#), [Fry J](#), [Kalton G](#).

Einführung

ISG

Facetten

Discus

Piriformis

Take Home

Kreuzschmerz (Low back Pain)

unspezifisch



80 - 85 %



[Scand J Work Environ Health](#) 1982 Jun;8(2):134-6.

Classification of low-back pain.

[Nachemson AL](#), [Andersson GB](#)

[Spine](#) 1982 Mar-Apr;7(2):141-9.

Synopsis: workshop on idiopathic low-back pain.

[White AA](#), [Gordon SL](#).

Einführung

ISG

Facetten

Discus

Piriformis

Take Home

Kreuzschmerz (Low back Pain)

unspezifisch



80 - 85 %



[Pain Med](#) (2011 Feb;12(2):224-33.

What is the source of chronic low back pain and does age play a role?

[DePalma MJ](#), [Ketchum JM](#), [Saullo T](#).

[Eur Spine J](#) (2007 Oct;16(10):1539-50.

Systematic review of tests to identify the disc, SIJ or facet joint as the source of low back pain.

[Hancock MJ](#), [Maher CG](#), [Latimer J](#), [Spindler MF](#), [McAuley JH](#), [Laslett M](#), [Bogduk N](#)

Einführung

ISG

Facetten

Discus

Piriformis


Take Home

Kreuzschmerz (Low back Pain)

unspezifisch



~~80 - 85 %~~



[Pain Med](#) (2011 Feb;12(2):224-33.

What is the source of chronic low back pain and does age play a role?

[DePalma MJ](#), [Ketchum JM](#), [Saullo T](#).

[Eur Spine J](#) (2007 Oct;16(10):1539-50.

Systematic review of tests to identify the disc, SIJ or facet joint as the source of low back pain.

[Hancock MJ](#), [Maher CG](#), [Latimer J](#), [Spindler MF](#), [McAuley JH](#), [Laslett M](#), [Bogduk N](#)

Einführung

ISG

Facetten

Discus

Piriformis


Take Home

Kreuzschmerz (Low back Pain)

unspezifisch



10 % !



[Pain Med](#) (2011 Feb;12(2):224-33.

What is the source of chronic low back pain and does age play a role?

[DePalma MJ](#), [Ketchum JM](#), [Saullo T](#).

[Eur Spine J](#) (2007 Oct;16(10):1539-50.

Systematic review of tests to identify the disc, SIJ or facet joint as the source of low back pain.

[Hancock MJ](#), [Maher CG](#), [Latimer J](#), [Spindler MF](#), [McAuley JH](#), [Laslett M](#), [Bogduk N](#)

Einführung

ISG

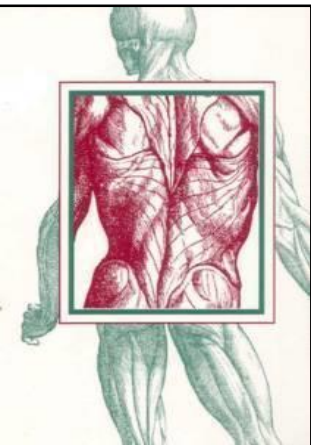
Facetten

Discus

Piriformis

Take Home

Spezifischer Kreuzschmerzen



Einführung

ISG

Facetten

Discus

Piriformis

Take Home

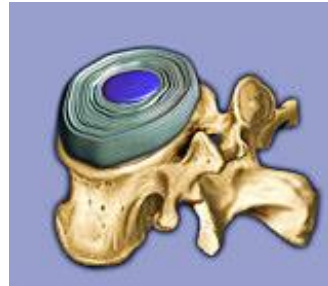
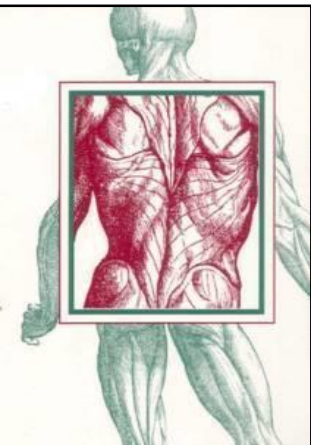
Source	Study	Age ⁺ (years)	Prevalence (%)	95% CI (%)	Prevalence (%)	95% CI (%)
IDD	Schwarzer (a)	36.7	39	(29, 49)	77.2	(67.0, 87.3)
	Manichikanti (b)	~47	26	(18, 34)	55.0	(45.4, 64.5)
FJP	Schwarzer (c)	38.4	15	(10, 20)	16.2	(8.1, 24.3)
	Schwarzer (d)	59	32	(20, 44)	40.7	(31.7, 49.8)
SIJP	Manichikanti (e)	~47	27	(22, 33)	27.5	(19.1, 36.0)
	Schwarzer (f)	32.8	30	(16, 44)	5.3	(0.7, 9.8)
	Schwarzer (f)	32.8	13	(6, 44)	5.3	(0.7, 9.8)
	Maigne (g)	45.3	18.5	—	12.9	(6.4, 19.5)

[Pain Med.](#) 2011 Feb;12(2):224-33.

What is the source of chronic low back pain and does age play a role?

[DePalma MJ](#), [Ketchum JM](#), [Saullo T](#).

Spezifischer Kreuzschmerzen



Source	Study	Age ⁺ (years)	Prevalence (%)	95% CI (%)	Prevalence (%)	95% CI (%)
IDD	Schwarzer (a)	36.7	39	(29, 49)	77.2	(67.0, 87.3)
	Manichikanti (b)	~47	26	(18, 34)	55.0	(45.4, 64.5)
FJP	Schwarzer (c)	38.4	15	(10, 20)	16.2	(8.1, 24.3)
	Schwarzer (d)	59	32	(20, 44)	40.7	(31.7, 49.8)
SIJP	Manichikanti (e)	~47	27	(22, 33)	27.5	(19.1, 36.0)
	Schwarzer (f)	32.8	30	(16, 44)	5.3	(0.7, 9.8)
	Schwarzer (f)	32.8	13	(6, 44)	5.3	(0.7, 9.8)
	Maigne (g)	45.3	18.5	—	12.9	(6.4, 19.5)

[Pain Med.](#) 2011 Feb;12(2):224-33.

What is the source of chronic low back pain and does age play a role?

[DePalma MJ](#), [Ketchum JM](#), [Saullo T](#).

Einführung

ISG

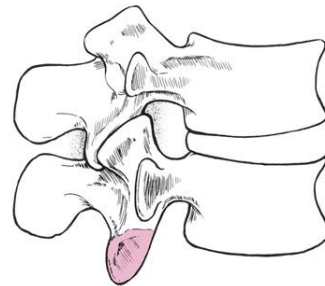
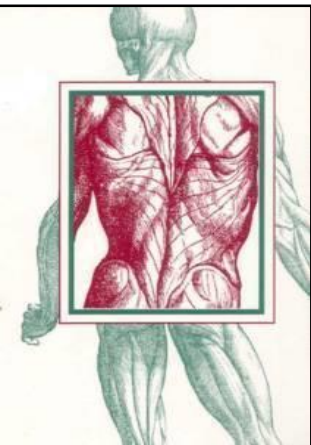
Facetten

Discus

Piriformis

Take Home

Spezifischer Kreuzschmerzen



Source	Study	Age ⁺ (years)	Prevalence (%)	95% CI (%)	Prevalence (%)	95% CI (%)
IDD	Schwarzer (a)	36.7	39	(29, 49)	77.2	(67.0, 87.3)
	Manichikanti (b)	~47	26	(18, 34)	55.0	(45.4, 64.5)
FJP	Schwarzer (c)	38.4	15	(10, 20)	16.2	(8.1, 24.3)
	Schwarzer (d)	59	32	(20, 44)	40.7	(31.7, 49.8)
SIJP	Manichikanti (e)	~47	27	(22, 33)	27.5	(19.1, 36.0)
	Schwarzer (f)	32.8	30	(16, 44)	5.3	(0.7, 9.8)
	Schwarzer (f)	32.8	13	(6, 44)	5.3	(0.7, 9.8)
	Maigne (g)	45.3	18.5	—	12.9	(6.4, 19.5)

[Pain Med.](#) 2011 Feb;12(2):224-33.

What is the source of chronic low back pain and does age play a role?

[DePalma MJ](#), [Ketchum JM](#), [Saullo T](#).

Einführung

ISG

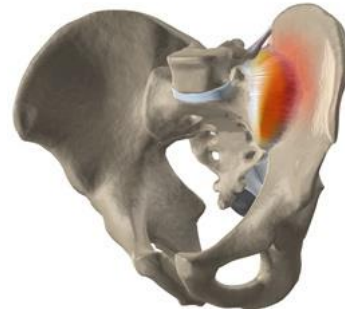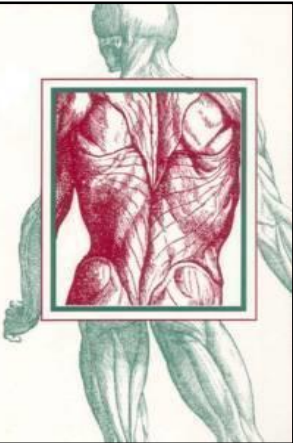
Facetten

Discus

Piriformis

Take Home

Spezifischer Kreuzschmerzen



Source	Study	Age ⁺ (years)	Prevalence (%)	95% CI (%)	Prevalence (%)	95% CI (%)
IDD	Schwarzer (a)	36.7	39	(29, 49)	77.2	(67.0, 87.3)
	Manichikanti (b)	~47	26	(18, 34)	55.0	(45.4, 64.5)
FJP	Schwarzer (c)	38.4	15	(10, 20)	16.2	(8.1, 24.3)
	Schwarzer (d)	59	32	(20, 44)	40.7	(31.7, 49.8)
SIJP	Manichikanti (e)	~47	27	(22, 33)	27.5	(19.1, 36.0)
	Schwarzer (f)	32.8	30	(16, 44)	5.3	(0.7, 9.8)
	Schwarzer (f)	32.8	13	(6, 44)	5.3	(0.7, 9.8)
	Maigne (g)	45.3	18.5	—	12.9	(6.4, 19.5)

[Pain Med.](#) 2011 Feb;12(2):224-33.

What is the source of chronic low back pain and does age play a role?

[DePalma MJ](#), [Ketchum JM](#), [Saullo T](#).

Einführung

ISG

Facetten

Discus

Piriformis

Take Home

Leitlinien spezifischer Kreuzschmerz

publiziert bei:  **AWMF online**
Das Portal der wissenschaftlichen Medizin



S2k-Leitlinie



Spezifischer Kreuzschmerz

AWMF Registernummer: 033-051

Stand vom Dezember 2017

Federführende Fachgesellschaft:

Deutsche Gesellschaft für Orthopädie und Orthopädische Chirurgie (DGOOC)

Federführende Autoren:

PD Dr. S. Kroppenstedt

Prof. Dr. A. Halder

Einführung

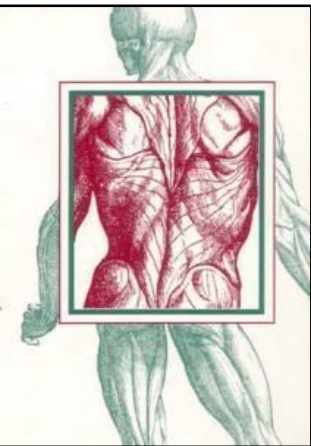
ISG

Facetten

Discus

Piriformis

Take Home



Morphologische Entitäten

- **Facettensyndrom**
- **Discogenes Lumbalsyndrom**
- **Axiale Spondyloarthritis**
- **Morbus Bastrup**
- **Spinalkanalstenose**
- **Spondylolyse und Spondylolisthese**
- Bandscheibenvorfall
- Osteoporotische Wirbelkörperfraktur
- Sakroiliakgelenk

https://www.awmf.org/uploads/tx_szleitlinien/033-051I_S2k_Spezifischer_Kreuzschmerz_2018-02.pdf

Einführung

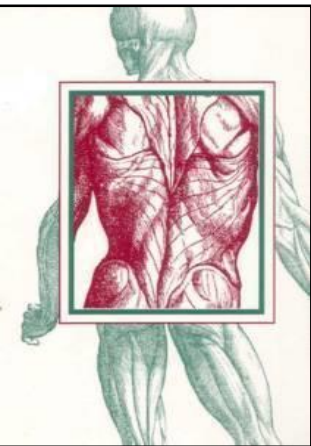
ISG

Facetten

Discus

Piriformis

Take Home



Morphologische Entitäten

- Facettensyndrom
- Discogenes Lumbalsyndrom
- **Axiale Spondyloarthritis**
- **Morbus Bastrup**
- **Spinalkanalstenose**
- **Spondylolyse und Spondylolisthese**
- Bandscheibenvorfall
- Osteoporotische Wirbelkörperfraktur
- Sakroiliakalgelenk

https://www.awmf.org/uploads/tx_szleitlinien/033-051I_S2k_Spezifischer_Kreuzschmerz_2018-02.pdf

Einführung

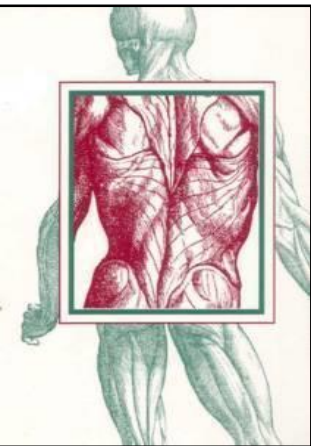
ISG

Facetten

Discus

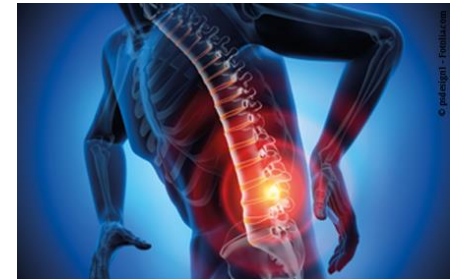
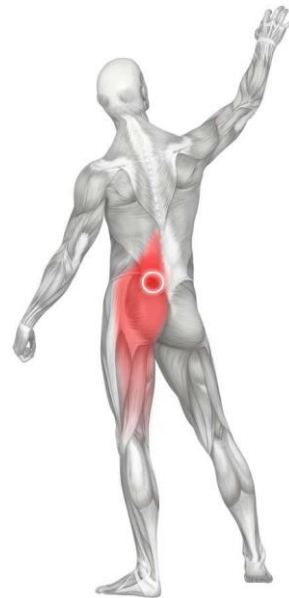Piriformis

Take Home



Funktionelle Entitäten

- Myogelosen
- Blockierung



Einführung

ISG

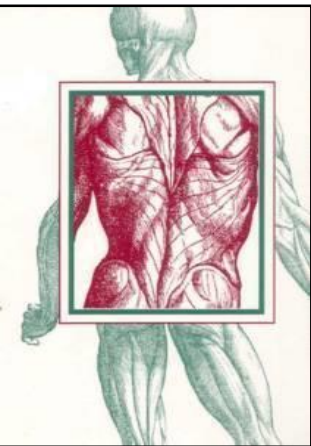
Facetten

Discus

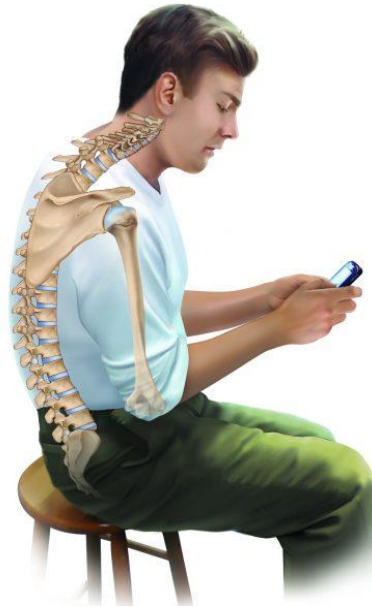Piriformis

Take Home

https://www.awmf.org/uploads/tx_szleitlinien/033-051I_S2k_Spezifischer_Kreuzschmerz_2018-02.pdf



Funktionelle Entitäten



Einführung

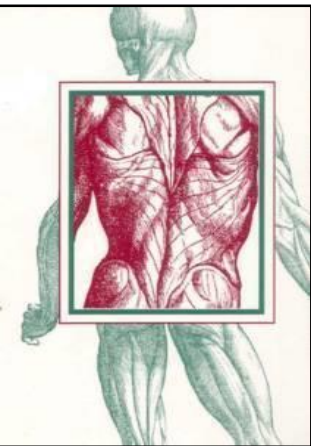
ISG

Facetten

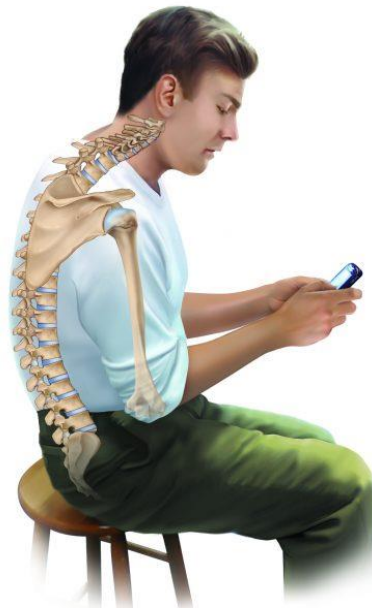Discus

Piriformis

Take Home



Funktionelle Entitäten



HARR

„Handy Assoziierter Rundrücken“

Einführung

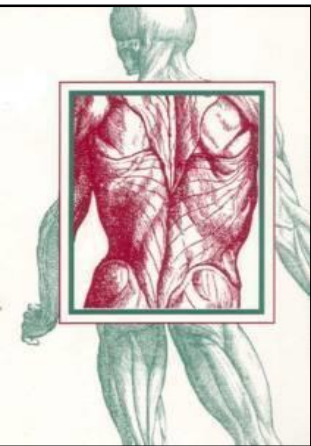
ISG

Facetten

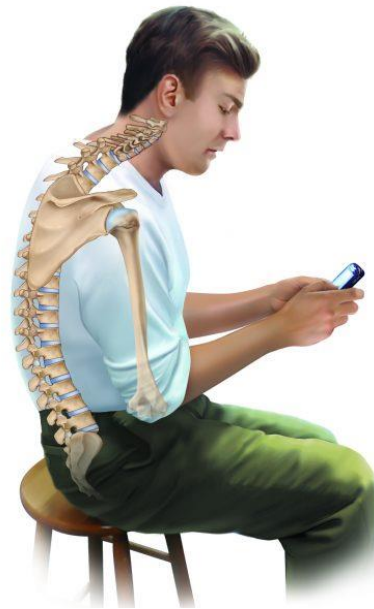Discus

Piriformis

Take Home



Funktionelle Entitäten



Einführung

ISG

Facetten

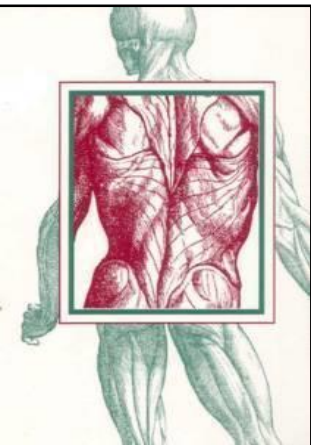
Discus

Piriformis

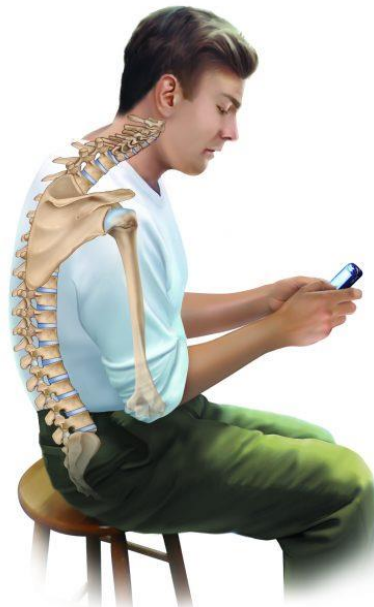Take Home

HARR

„Handy Assoziierter Rundrücken“



Funktionelle Entitäten



HARR

„Handy Assoziierter Rundrücken“



HOPS

„Home Office Pain Syndrom“

Einführung

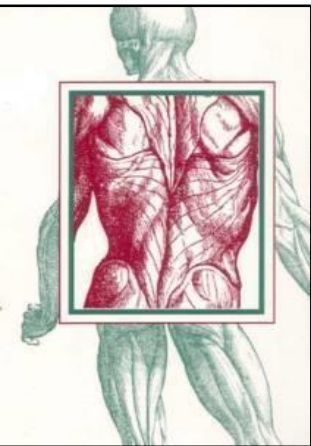
ISG

Facetten

Discus

Piriformis

Take Home



Triggerpunkte

Einführung

ISG

Facetten

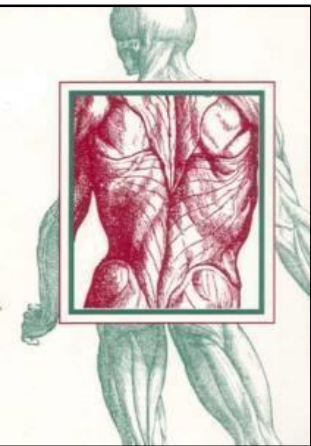
Discus

Piriformis

Take Home

Triggerpunkte

- strangförmig zu tastende Verhärtung



Einführung

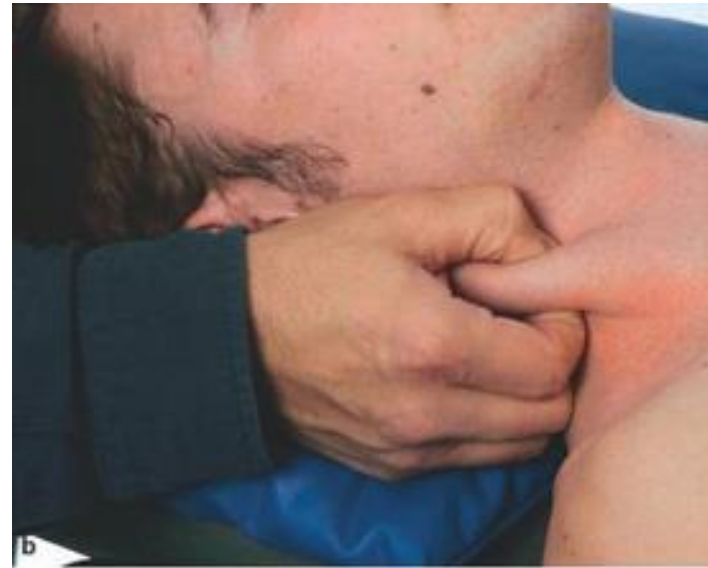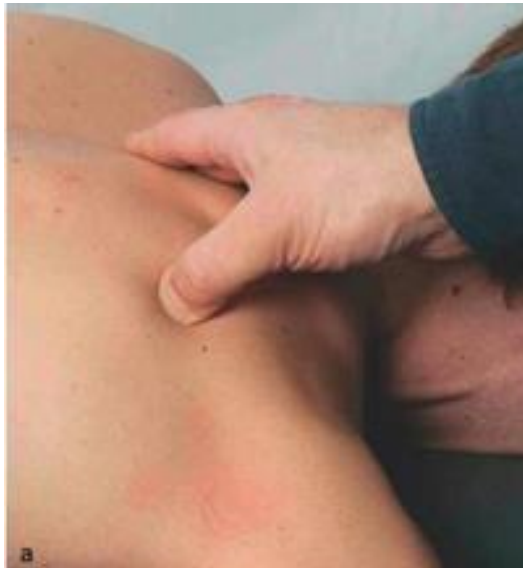ISG

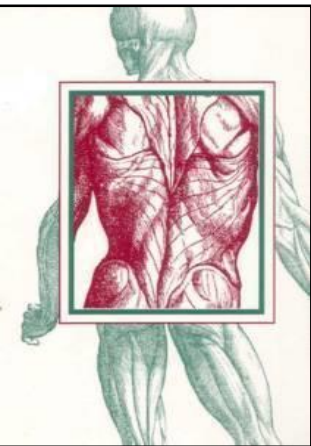
Facetten

Discus

Piriformis

Take Home





Triggerpunkte

- strangförmig zu tastende Verhärtung
- lokale Druckschmerzempfindlichkeit

Einführung

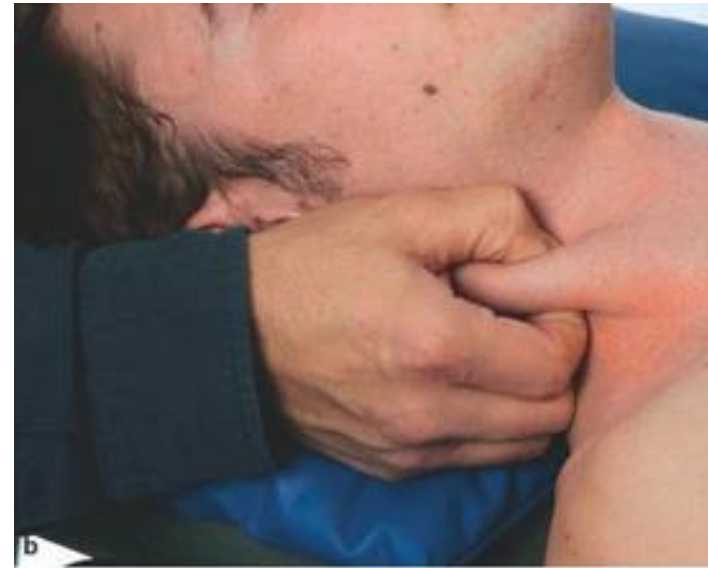ISG

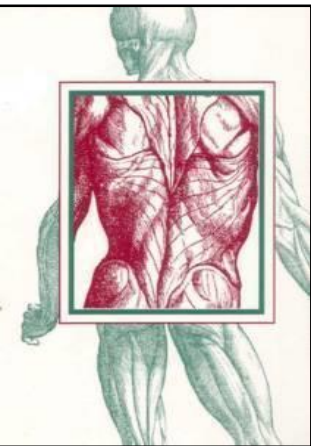
Facetten

Discus

Piriformis

Take Home





Triggerpunkte

- strangförmig zu tastende Verhärtung
- lokale Druckschmerzempfindlichkeit
- „referred pain“

Einführung

ISG

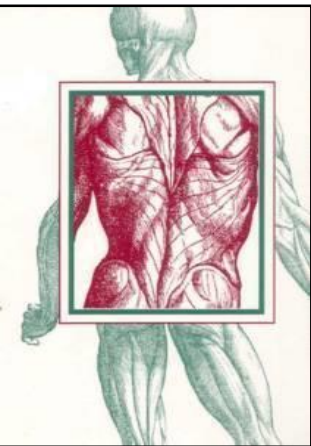
Facetten

Discus

Piriformis

Take Home

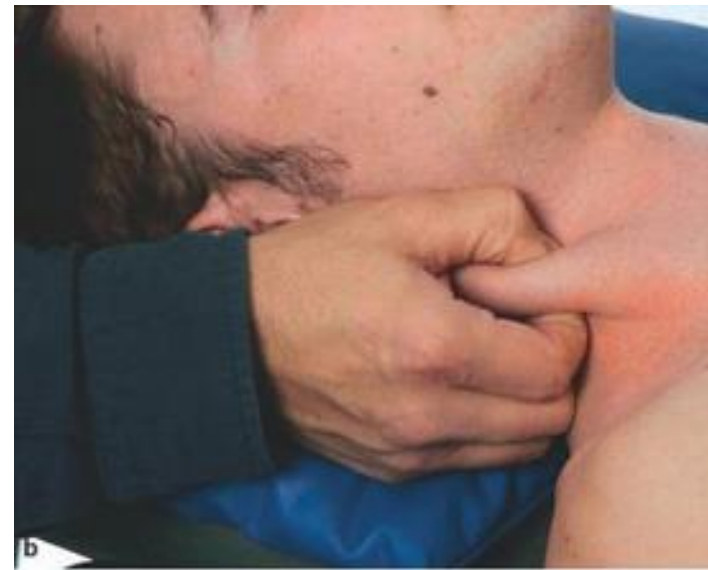
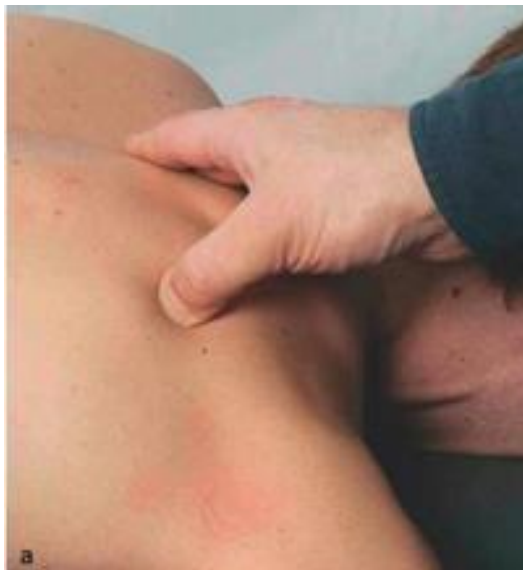


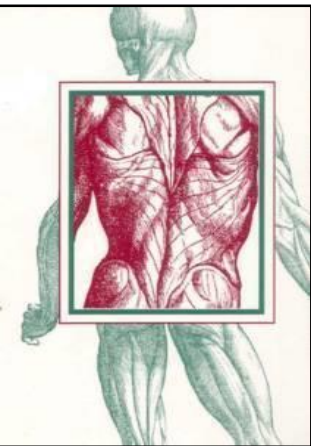
Triggerpunkte

- strangförmig zu tastende Verhärtung
- lokale Druckschmerzempfindlichkeit
- „referred pain“
- lokale Zuckungsreaktion („local switch response“)

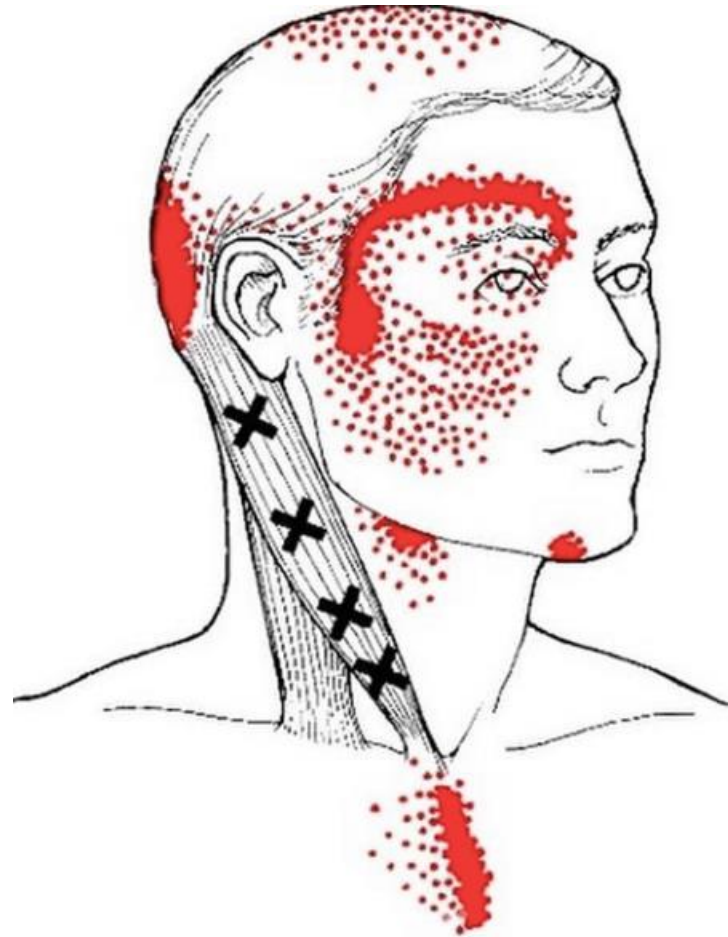
Einführung
ISG
Facetten
Discus
Piriformis
Take Home



Spezifischer Kreuzschmerzen



M. sternocleidomasteus



Einführung

ISG

Facetten

Discus

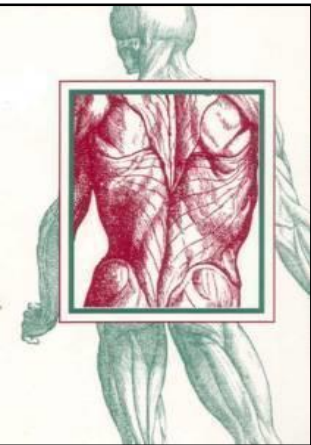
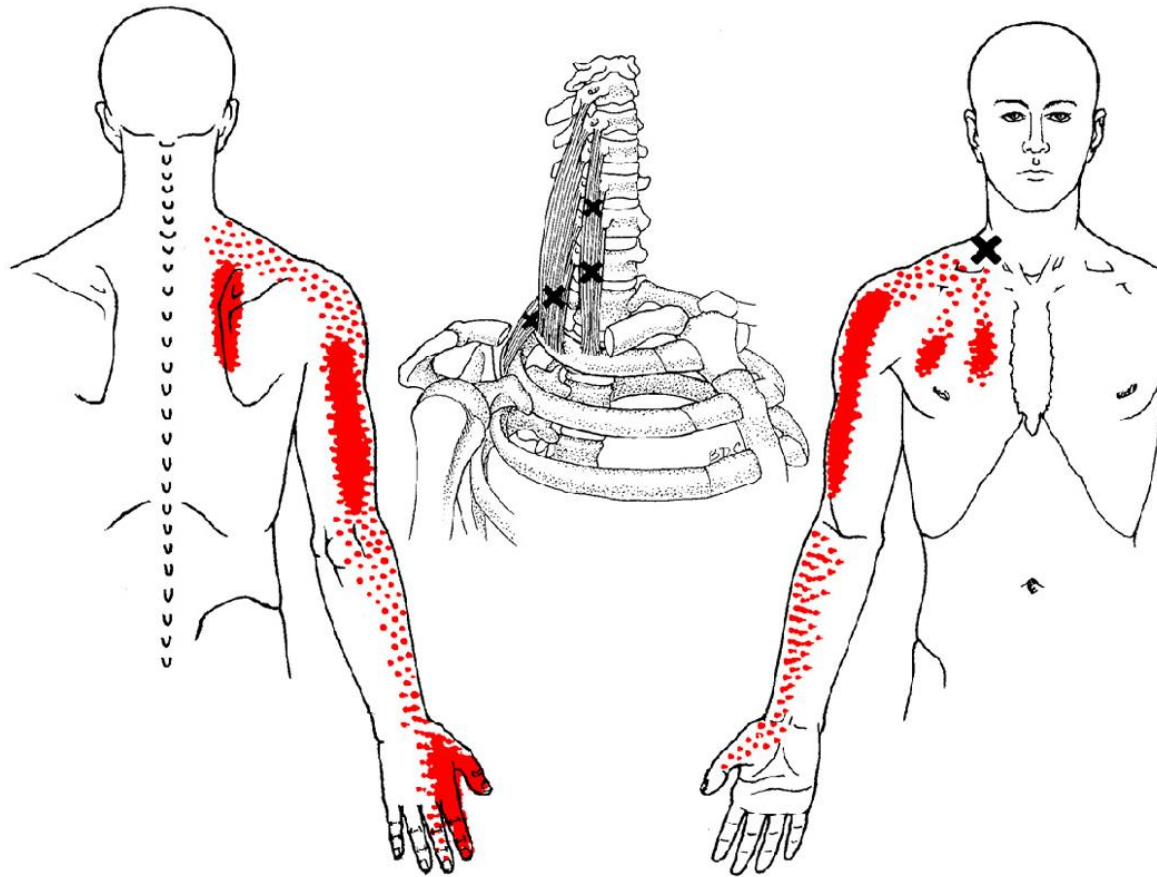
Piriformis

Take Home

<https://www.gesundheitspraxis-sw.ch/post/nacken-und-oder-kopfschmerzen-teil-2-der-sternocleidomastoideus-muskel>

Spezifischer Kreuzschmerzen

Mm. scaleni

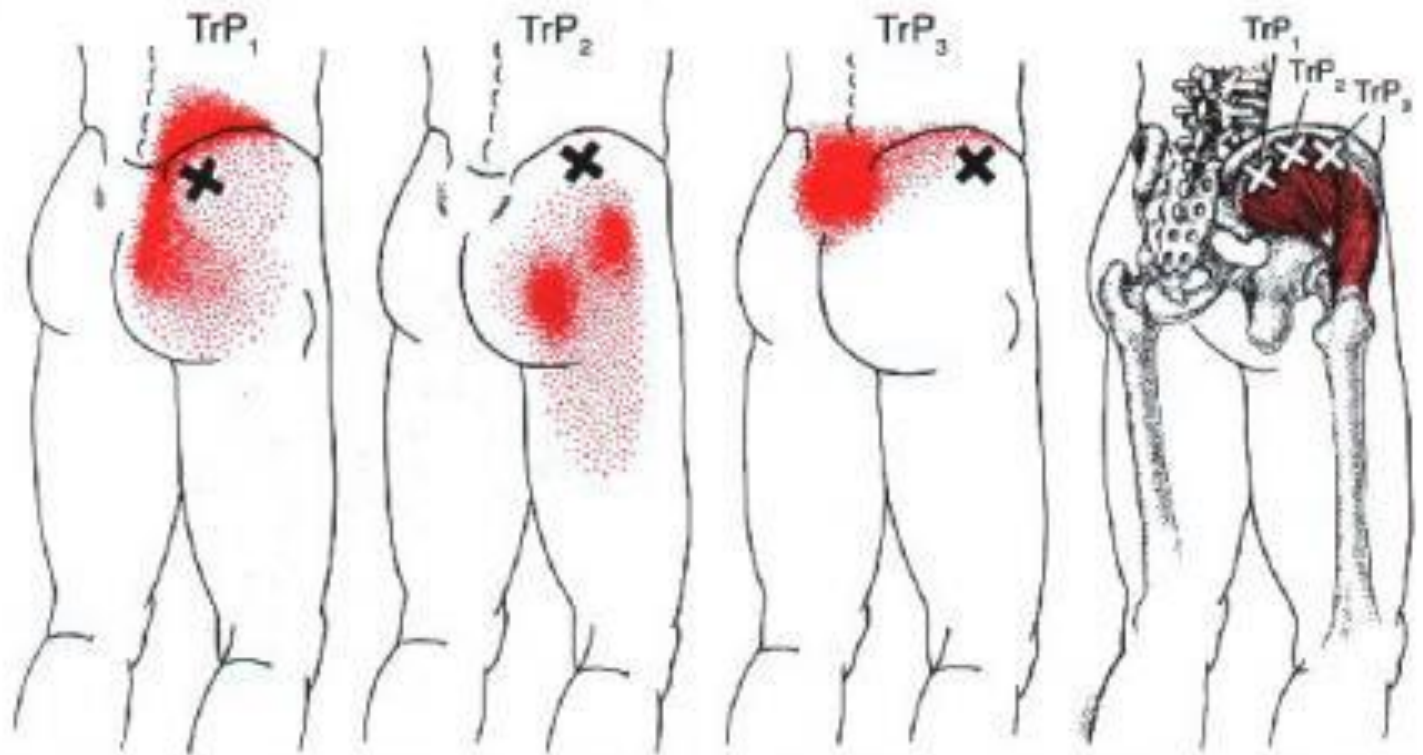
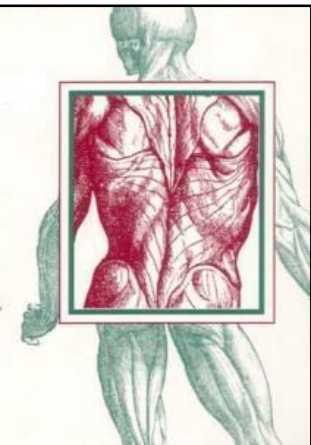


- Einführung
- ISG
- Facetten
- Discus
- Piriformis
- Take Home

<https://www.physiotherapie-binningen.ch/triggerpunkt-therapie/>

Spezifischer Kreuzschmerzen

M. Gluteus medius



Einführung

ISG

Facetten

Discus

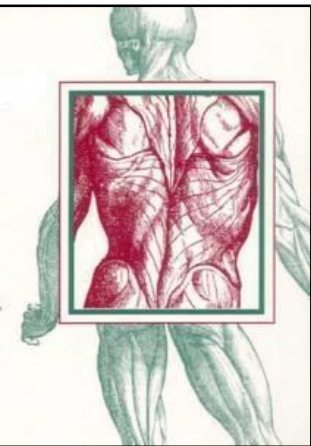
Piriformis

Take Home

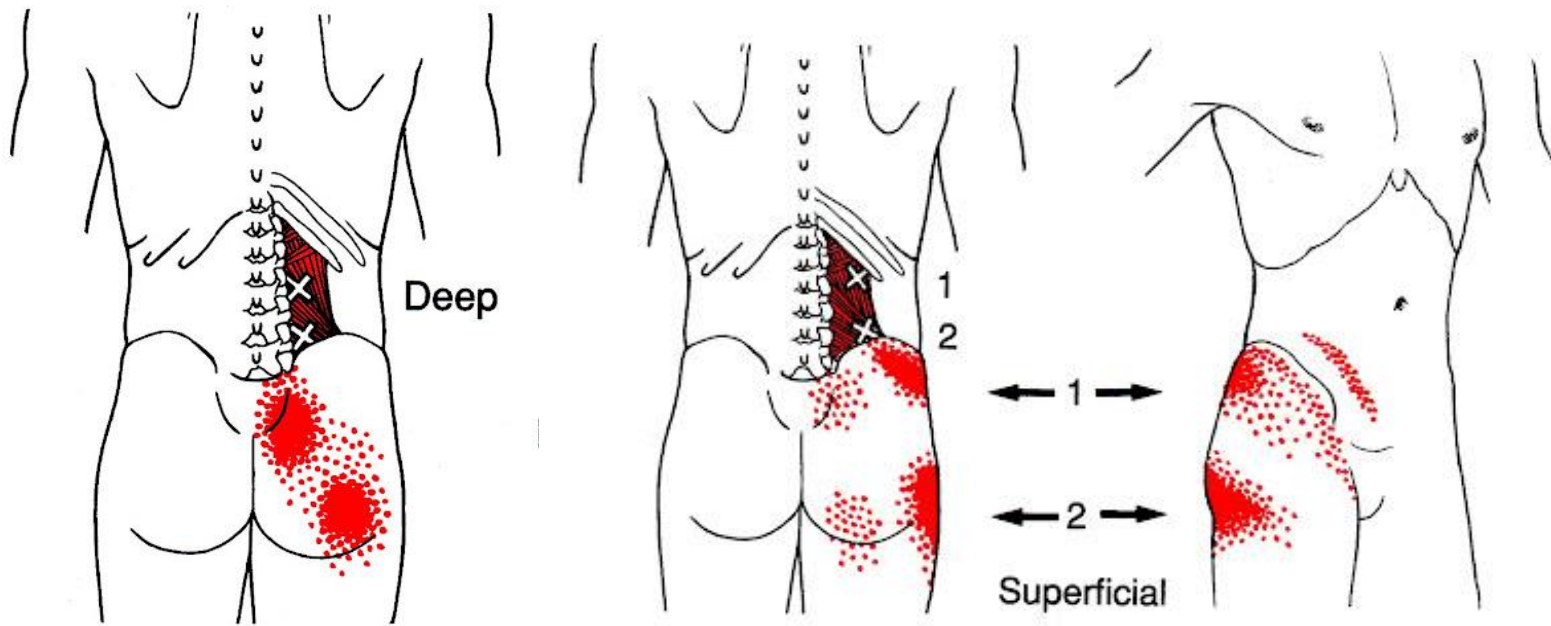
<http://www.triggerpoints.net/de/muscle>

Spezifischer Kreuzschmerzen

M. quadratus lumborum

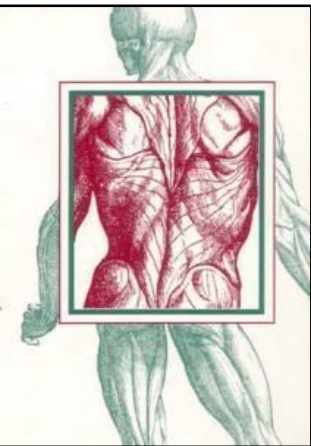


- Einführung
- ISG
- Facetten
- Discus
- Piriformis
- Take Home

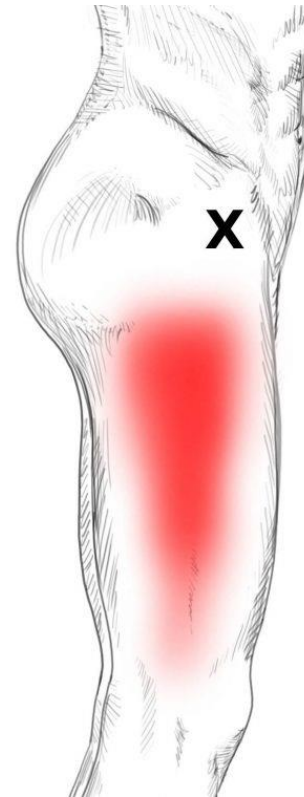
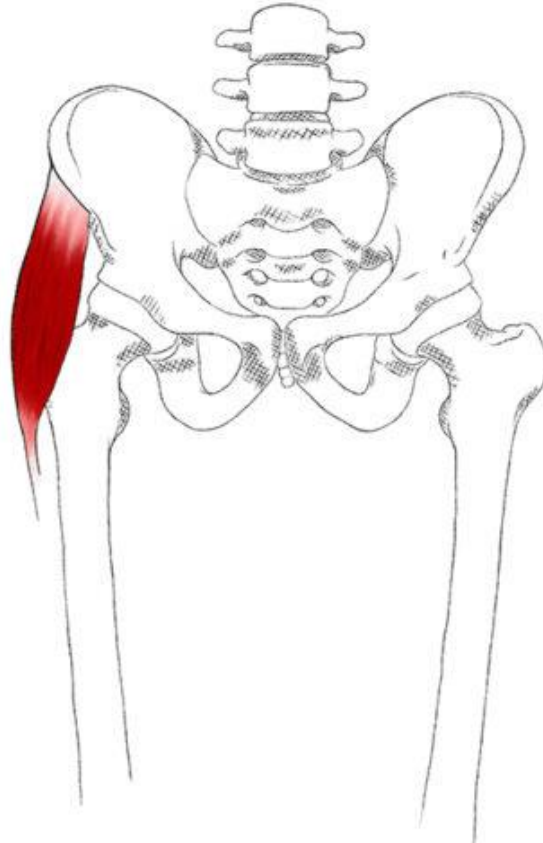


<http://www.triggerpoints.net/de/muscle/quadratischer-lendenmuskel>

Spezifischer Kreuzschmerzen



M. tensor fasciae latae



Einführung

ISG

Facetten

Discus

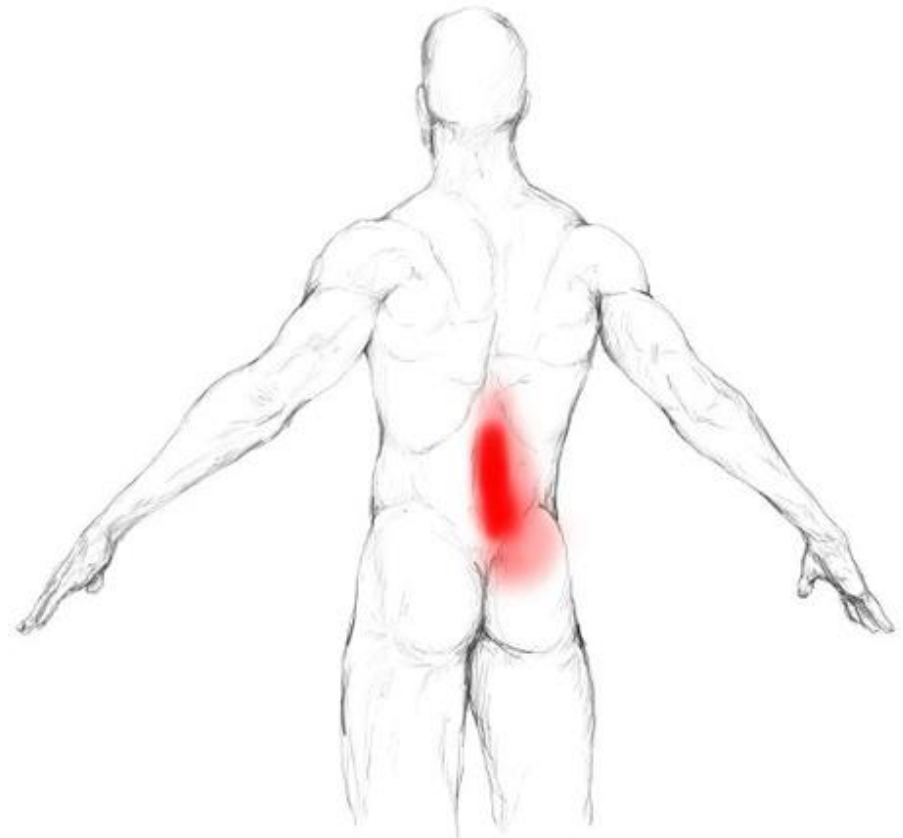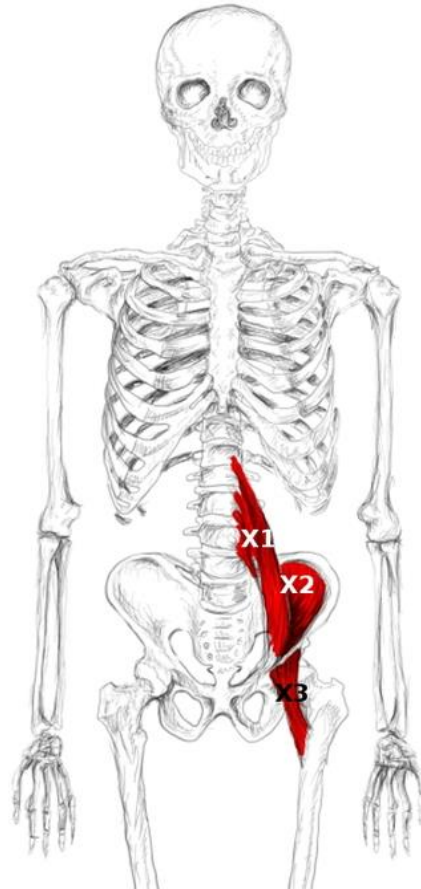
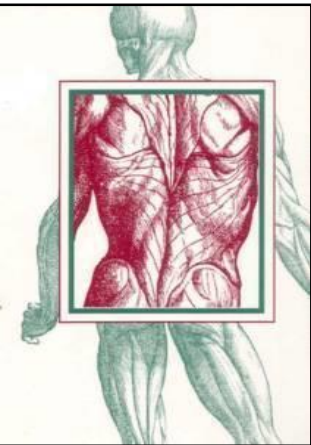
Piriformis

Take Home

<https://www.muskel-und-gelenkschmerzen.de/triggerpunkte>

Spezifischer Kreuzschmerzen

M. iliopsoas



Einführung

ISG

Facetten

Discus

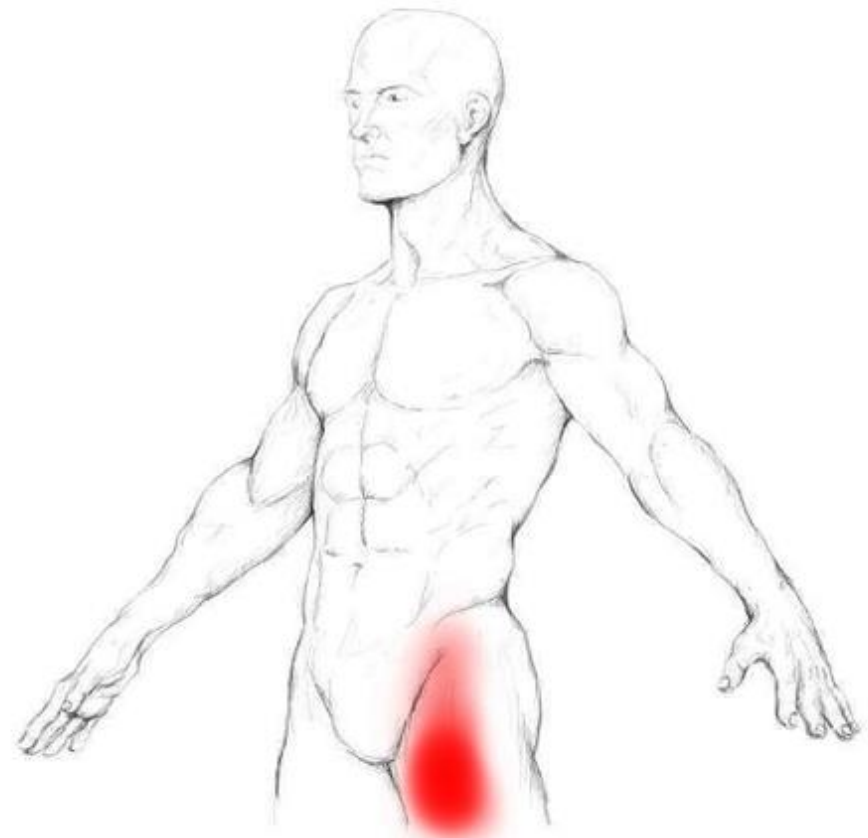
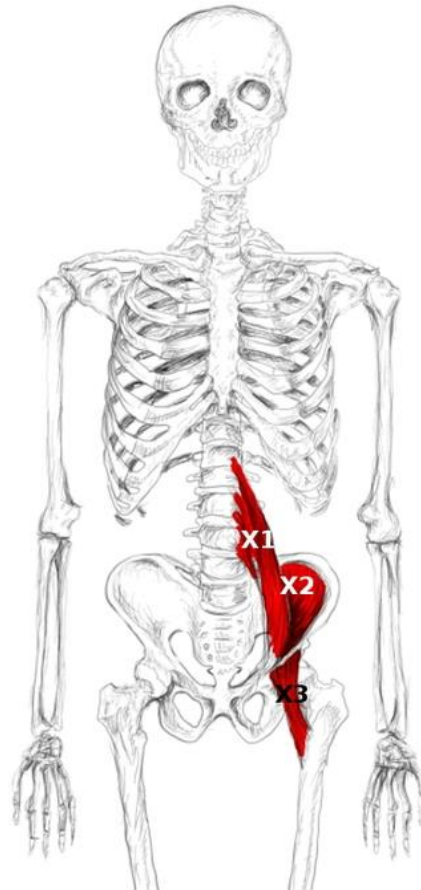
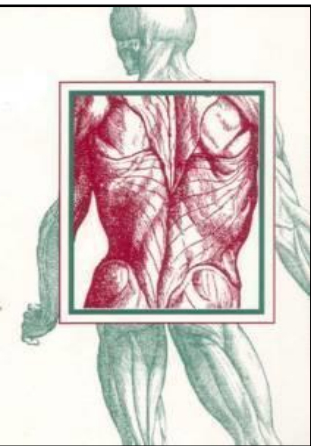
Piriformis

Take Home

<https://www.muskel-und-gelenkschmerzen.de/triggerpunkte>

Spezifischer Kreuzschmerzen

M. iliopsoas



Einführung

ISG

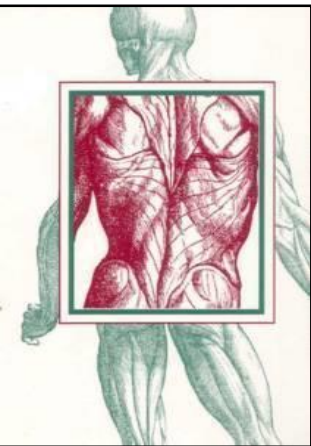
Facetten

Discus

Piriformis

Take Home

<https://www.muskel-und-gelenkschmerzen.de/triggerpunkte>



Triggerpunkte

Therapieansatz: multimodal

Einführung

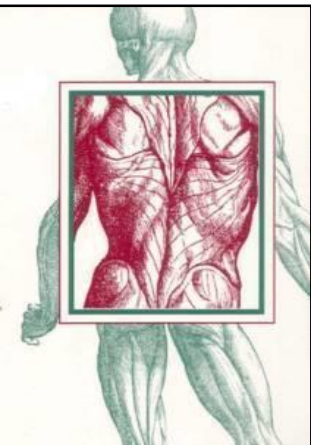
ISG

Facetten

Discus

Piriformis

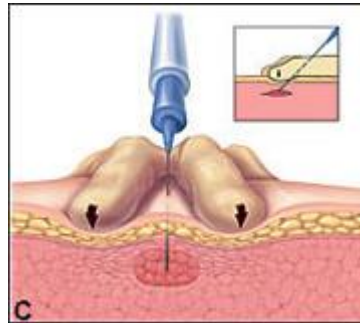
Take Home



Triggerpunkte

Therapieansatz: multimodal

- direkte Triggerpunkt Behandlung



Einführung

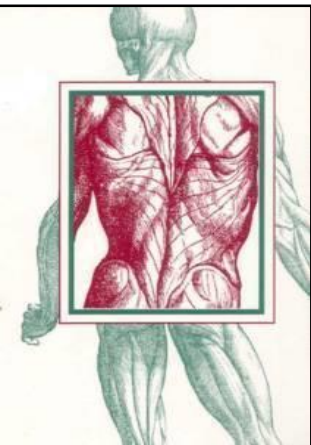
ISG

Facetten

Discus

Piriformis

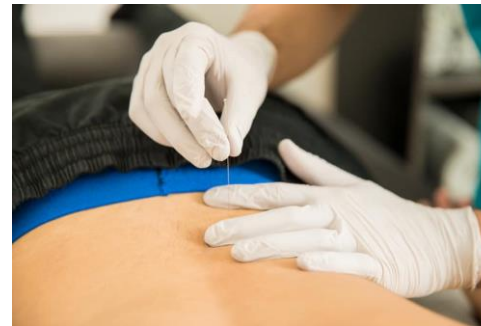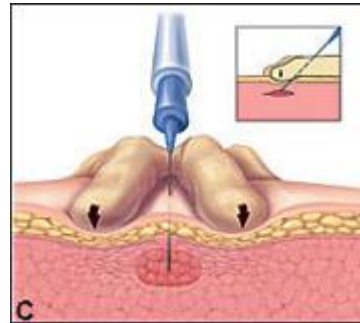
Take Home



Triggerpunkte

Therapieansatz: multimodal

- direkte Triggerpunkt Behandlung



Einführung

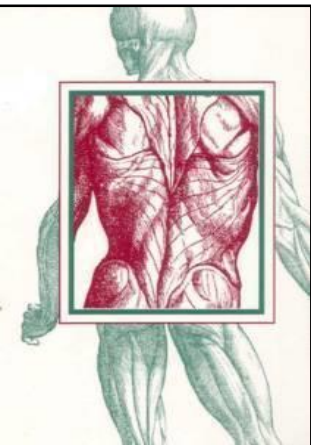
ISG

Facetten

Discus

Piriformis

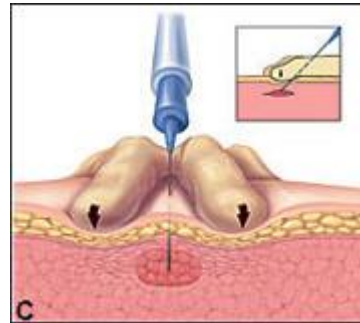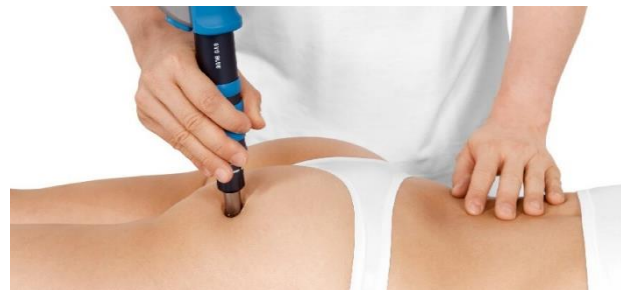
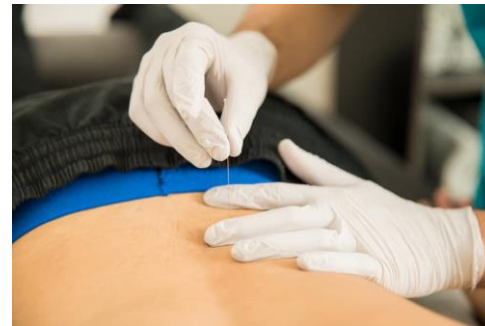Take Home



Triggerpunkte

Therapieansatz: multimodal

- direkte Triggerpunkt Behandlung



Einführung

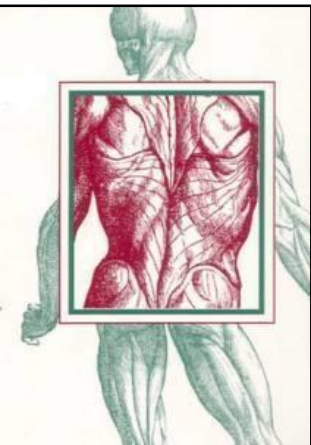
ISG

Facetten

Discus

Piriformis

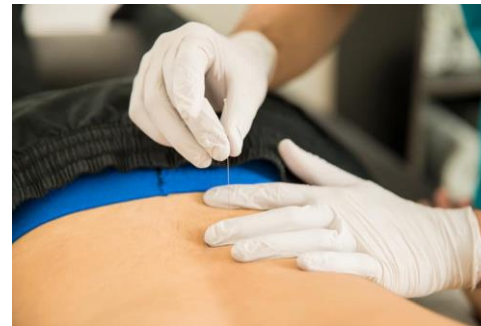
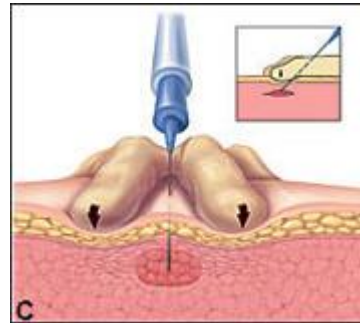
Take Home



Triggerpunkte

Therapieansatz: multimodal

- direkte Triggerpunkt Behandlung



Einführung

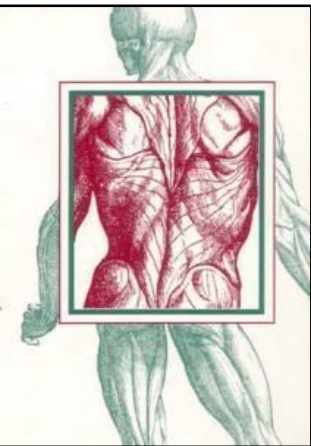
ISG

Facetten

Discus

Piriformis

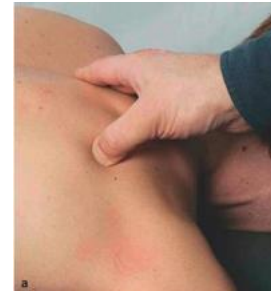Take Home



Triggerpunkte

Therapieansatz: multimodal

- direkte Triggerpunkt Behandlung



Einführung

ISG

Facetten

Discus

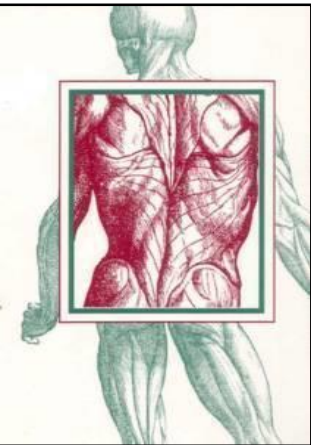
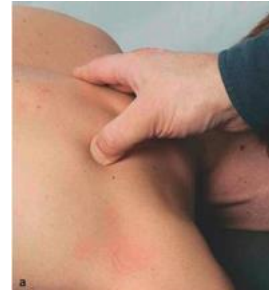Piriformis

Take Home

Triggerpunkte

Therapieansatz: multimodal

- direkte Triggerpunkt Behandlung
- Physiotherapie:
 - Propriozeption
 - segmentale Stabilisation



Einführung

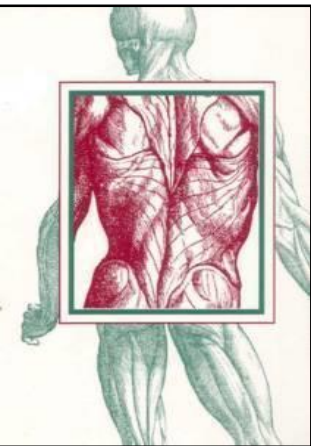
ISG

Facetten

Discus

Piriformis

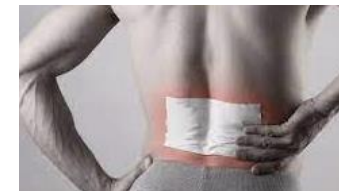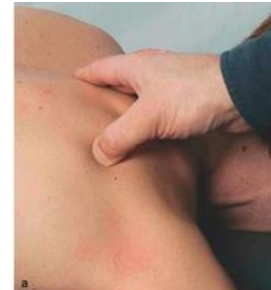Take Home



Triggerpunkte

Therapieansatz: multimodal

- direkte Triggerpunkt Behandlung
- Physiotherapie:
 - Propriozeption
 - segmentale Stabilisation
- Wärme



Einführung

ISG

Facetten

Discus

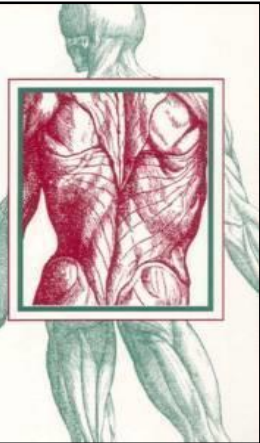
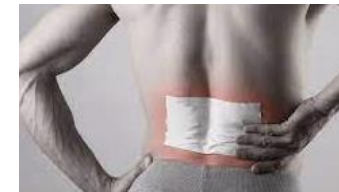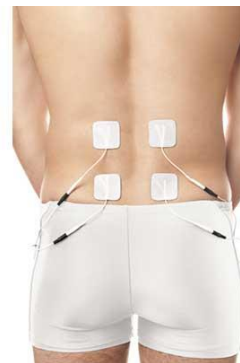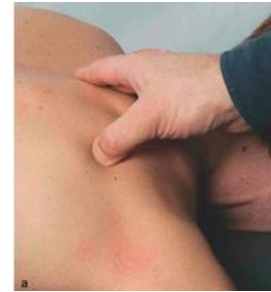Piriformis

Take Home

Triggerpunkte

Therapieansatz: multimodal

- direkte Triggerpunkt Behandlung
- Physiotherapie:
 - Propriozeption
 - segmentale Stabilisation
- Wärme
- Elektrotherapie (TENS)



Einführung

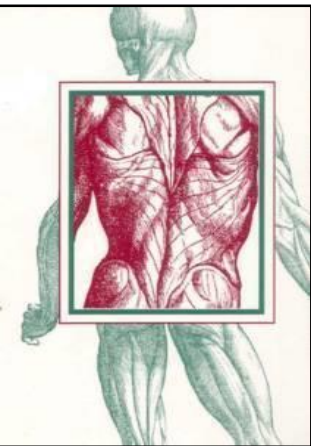
ISG

Facetten

Discus

Piriformis

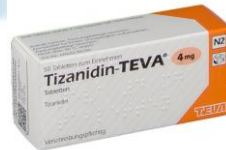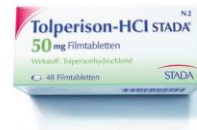Take Home



Triggerpunkte

Therapieansatz: multimodal

- direkte Triggerpunkt Behandlung
- Physiotherapie:
 - Propriozeption
 - segmentale Stabilisation
- Wärme
- Elektrotherapie (TENS)
- medikamentös



Einführung

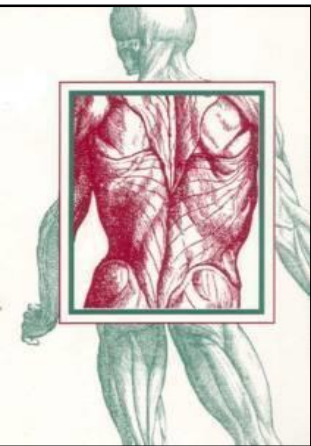
ISG

Facetten

Discus

Piriformis

Take Home



Triggerpunkte

Therapieansatz: multimodal

- direkte Triggerpunkt Behandlung
- Physiotherapie



Einführung

ISG

Facetten

Discus

Piriformis

Take Home

Spezifischer Kreuzschmerzen

Iliosacralgelenk

Einführung

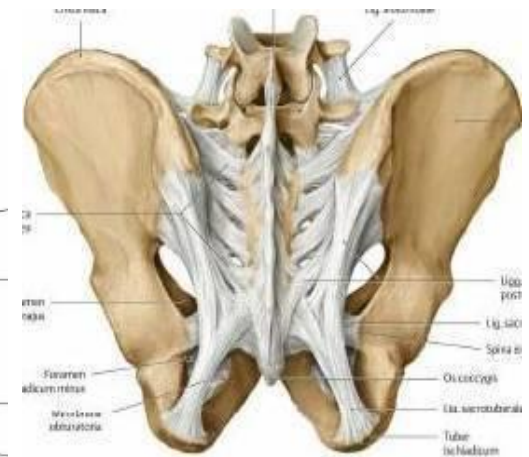
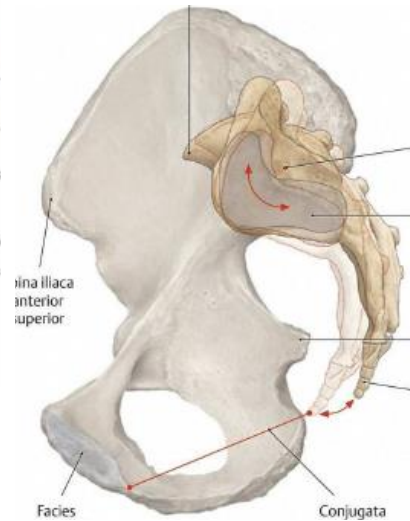
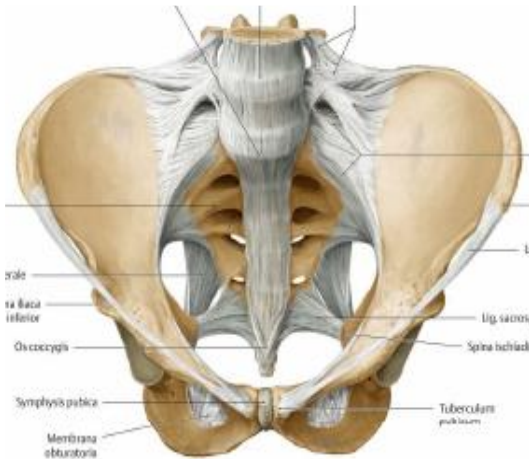
ISG

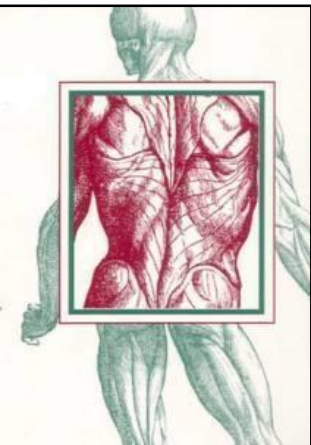
Facetten

Discus

Piriformis

Take Home





Iliosacralgelenk

[Man Ther.](#) 2000 Feb;5(1):30-6.

Clinical tests of the sacroiliac joint. A systematic methodological review. Part 1: Reliability.

[van der Wurff P](#), [Hagmeijer RH](#), [Meyne W](#).

[Man Ther.](#) 2000 May;5(2):89-96.

Clinical tests of the sacroiliac joint.

[van der Wurff P](#), [Meyne W](#), [Hagmeijer RH](#).

[Man Ther.](#) 2007 Feb;12(1):72-9. Epub 2006 Jul 12.

The reliability of selected motion- and pain provocation tests for the sacroiliac joint.

[Robinson HS](#), [Brox JI](#), [Robinson R](#), [Bjelland E](#), [Solem S](#), [Telje T](#)

[Aust J Physiother.](#) 2003;49(2):89-97.

Diagnosing painful sacroiliac joints: A validity study of a McKenzie evaluation and sacroiliac provocation tests.

[Laslett M](#), [Young SB](#), [Aprill CN](#), [McDonald B](#).

[Aust J Physiother.](#) 2006;52(3):229.

Pain provocation tests for diagnosis of sacroiliac joint pain.

[Laslett M](#).

Einführung

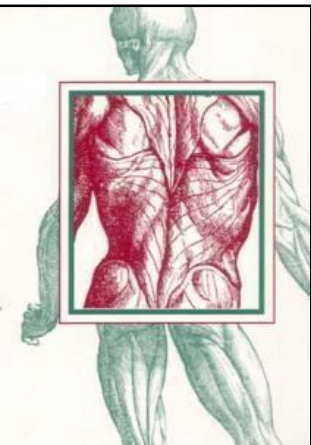
ISG

Facetten

Discus

Piriformis

Take Home



Iliosacralgelenk

[Man Ther.](#) 2000 Feb;5(1):30-6.

Clinical tests of the sacroiliac joint. A systematic methodological review. Part 1: Reliability.

[van der Wurff P](#), [Hagmeijer RH](#), [Meyne W](#).

[Man Ther.](#) 2000 May;5(2):89-96.

Clinical tests of the sacroiliac joint.

[van der Wurff P](#), [Meyne W](#), [Hagmeijer RH](#).

[Man Ther.](#) 2007 Feb;12(1):72-9. Epub 2006 Jul 12.

The reliability of selected motion- and pain provocation tests for the sacroiliac joint.

[Robinson HS](#), [Brox JI](#), [Robinson R](#), [Bjelland E](#), [Solem S](#), [Telje T](#)

[Aust J Physiother.](#) 2003;49(2):89-97.

Diagnosing painful sacroiliac joints: A validity study of a McKenzie evaluation and sacroiliac provocation tests.

[Laslett M](#), [Young SB](#), [Aprill CN](#), [McDonald B](#).

[Aust J Physiother.](#) 2006;52(3):229.

Pain provocation tests for diagnosis of sacroiliac joint pain.

[Laslett M](#).

Einführung

ISG

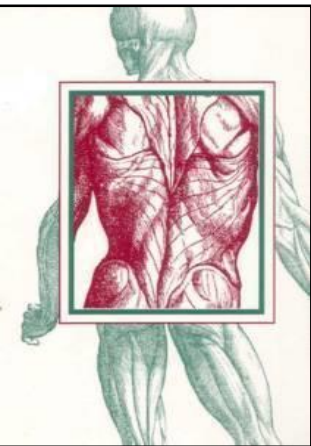
Facetten

Discus

Piriformis

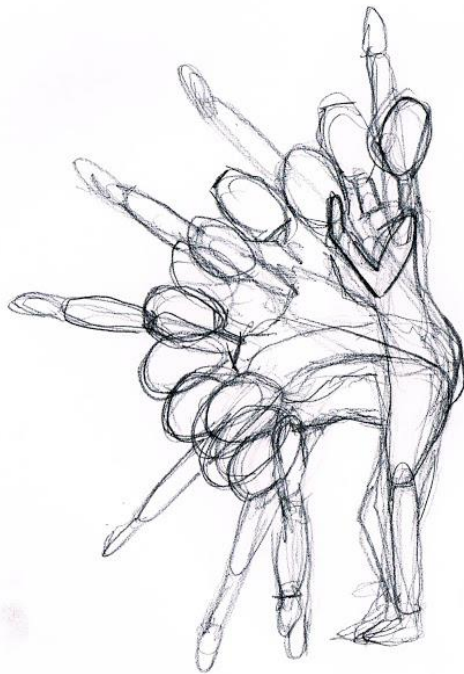Take Home

Spezifischer Kreuzschmerzen



Iliosacralgelenk

Funktion



Einführung

ISG

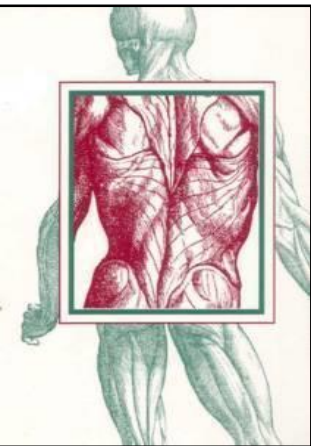
Facetten

Discus

Piriformis

Take Home

Spezifischer Kreuzschmerzen



Iliosacralgelenk

Funktion



Provokation



Einführung

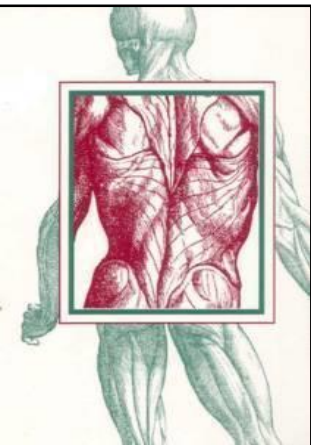
ISG

Facetten

Discus

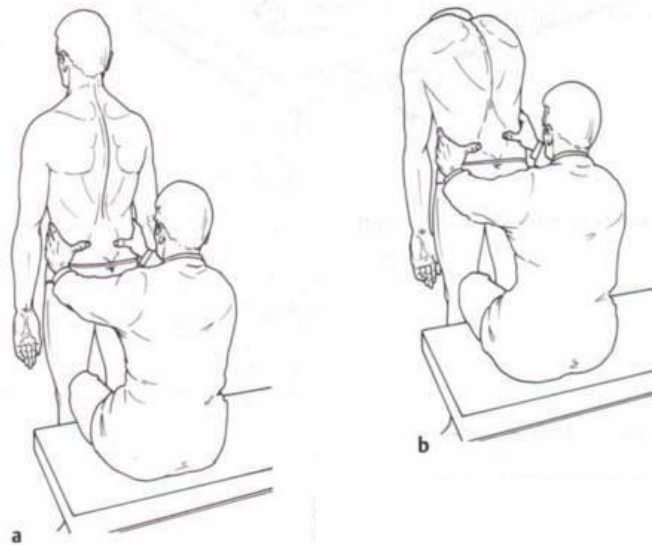
Piriformis

Take Home



Iliosacralgelenk

Funktion



„Vorlauf“

Einführung

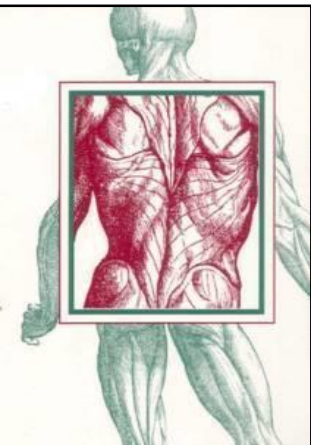
ISG

Facetten

Discus

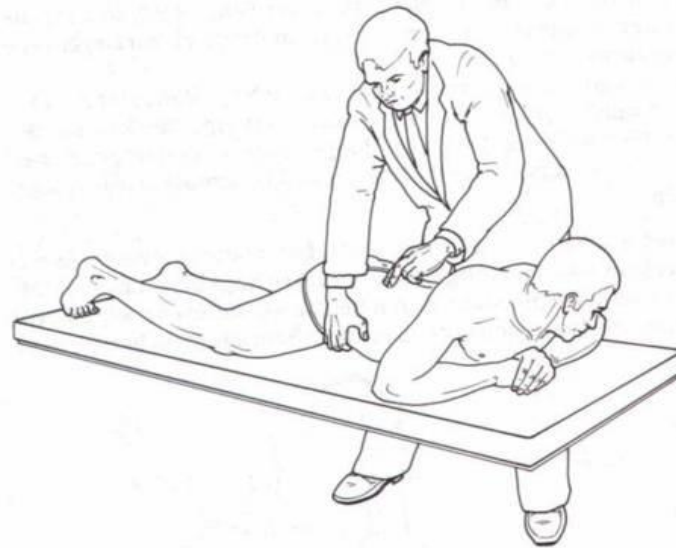Piriformis

Take Home



Iliosacralgelenk

Funktion



„Schütteltest“

Einführung

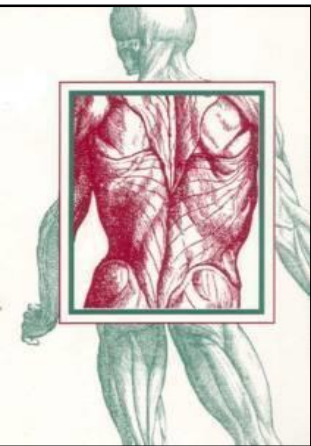
ISG

Facetten

Discus

Piriformis

Take Home



Iliosacralgelenk

Funktion



„Federungstest“

Einführung

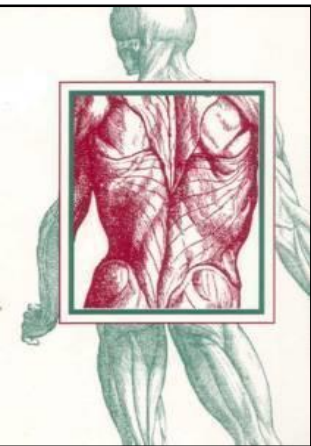
ISG

Facetten

Discus

Piriformis

Take Home



Iliosacralgelenk

Provokation



„Distraction“
adaptiert nach Vleeming

Einführung

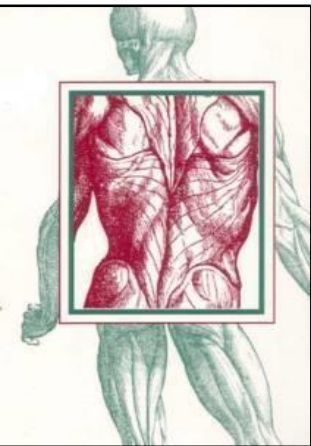
ISG

Facetten

Discus

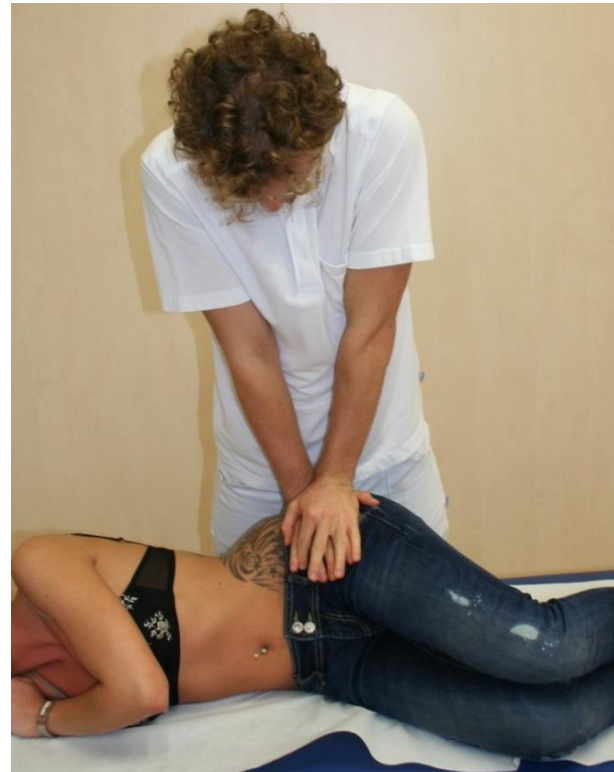Piriformis

Take Home



Iliosacralgelenk

Provokation



„Compression“

Einführung

ISG

Facetten

Discus

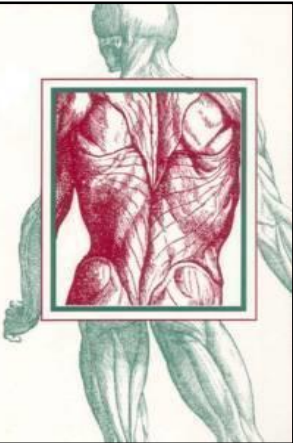
Piriformis

Take Home

Iliosacralgelenk

Provokation

„thigh thrust“



Einführung

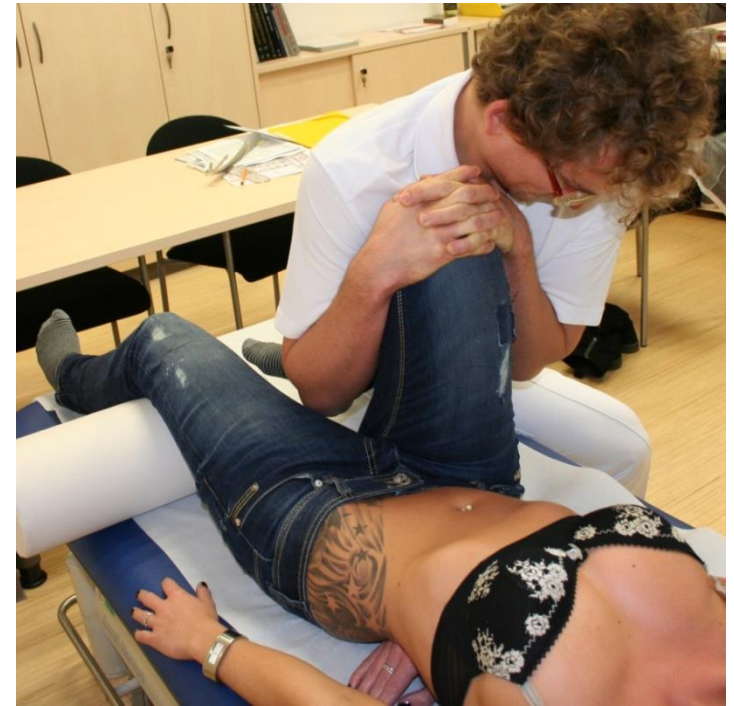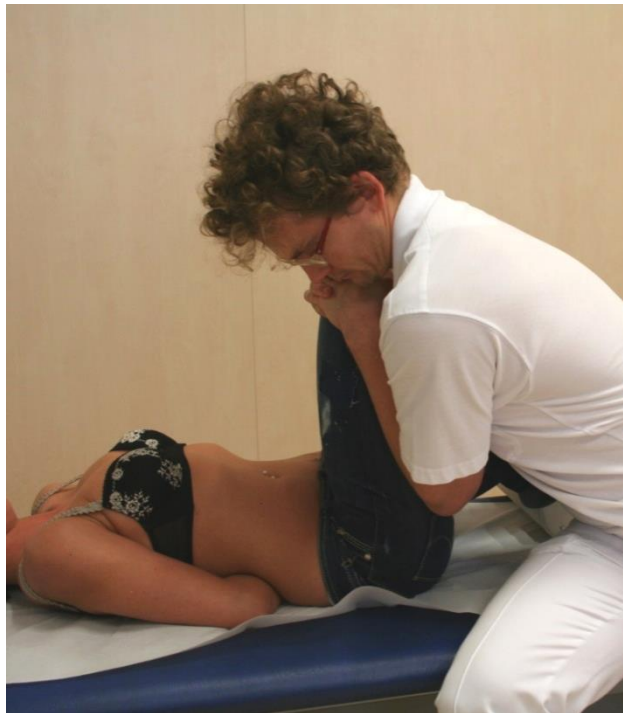ISG

Facetten

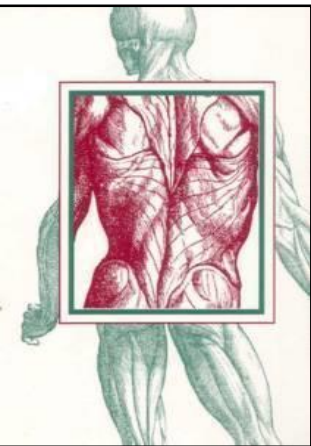
Discus

Piriformis

Take Home

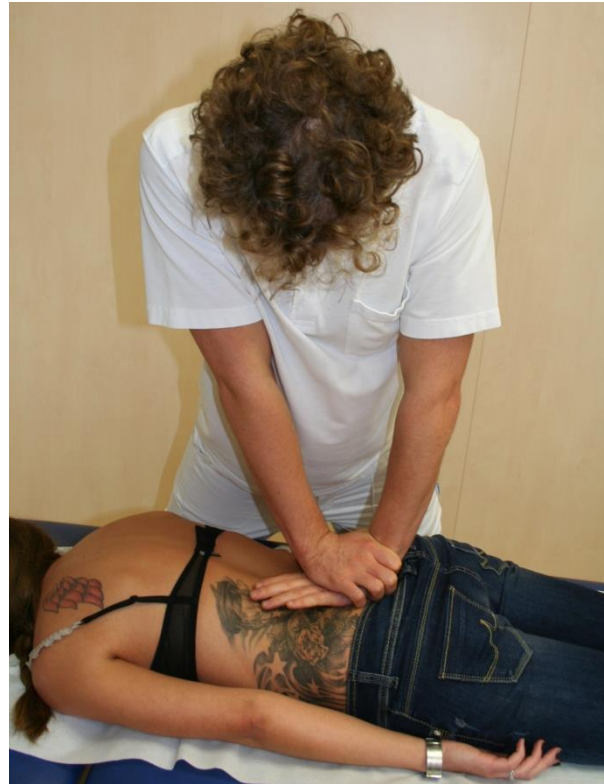


Spezifischer Kreuzschmerzen



Iliosacralgelenk

Provokation



„sacral thrust“

Einführung

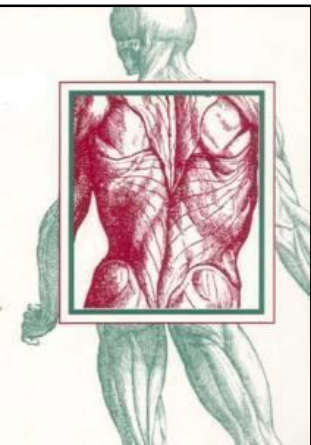
ISG

Facetten

Discus

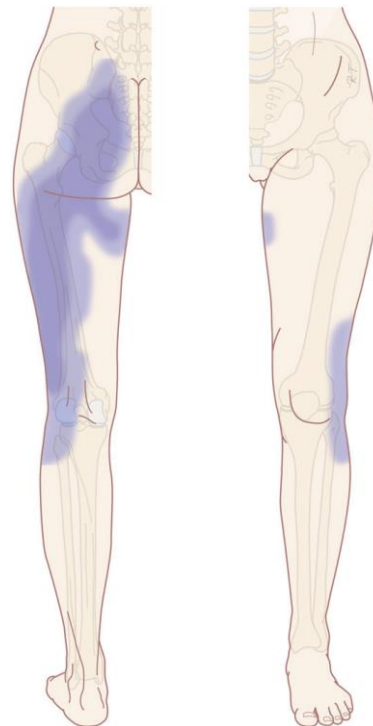Piriformis

Take Home



Iliosacralgelenk

Schmerzprojektion bei ISG Affektion :



Vanelderen et. al,
Pain Pract 2010

Einführung

ISG

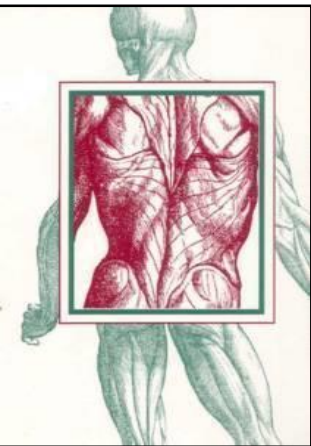
Facetten

Discus

Piriformis

Take Home

Spezifischer Kreuzschmerzen



Iliosacralgelenk

Therapie

Einführung

ISG

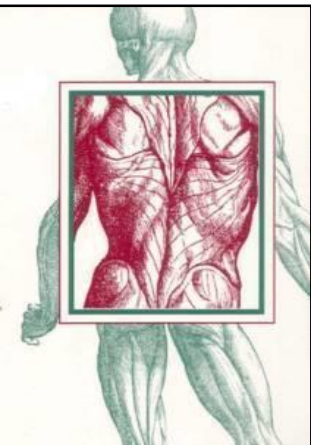
Facetten

Discus

Piriformis

Take Home

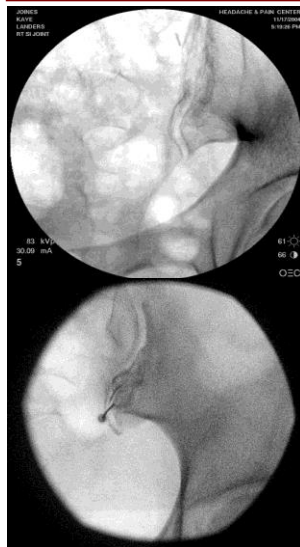
Spezifischer Kreuzschmerzen



Iliosacralgelenk

Therapie

Infiltration



Einführung

ISG

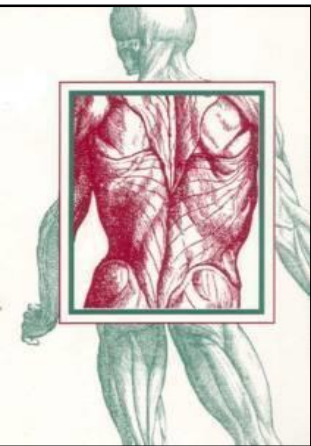
Facetten

Discus

Piriformis

Take Home

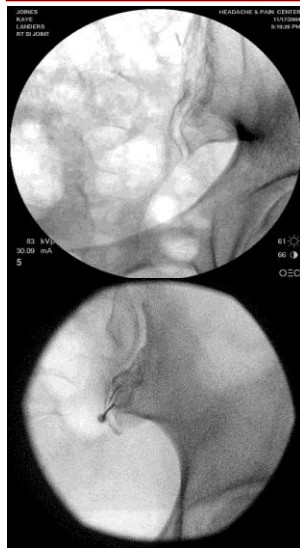
Spezifischer Kreuzschmerzen



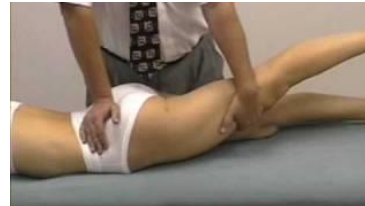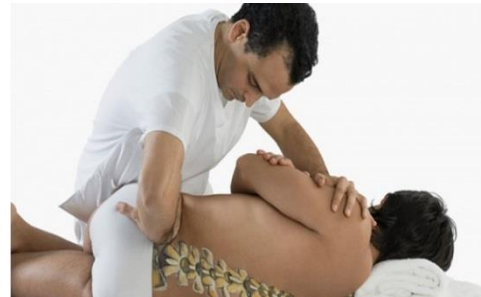Iliosacralgelenk

Therapie

Infiltration



Manuelle Medizin



Einführung

ISG

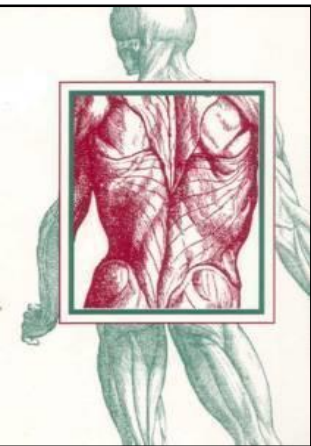
Facetten

Discus

Piriformis

Take Home

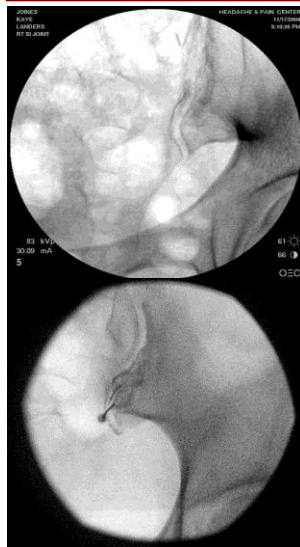
Spezifischer Kreuzschmerzen



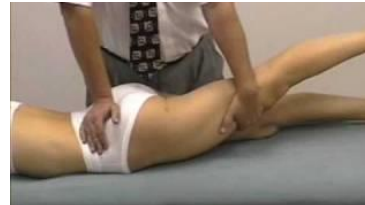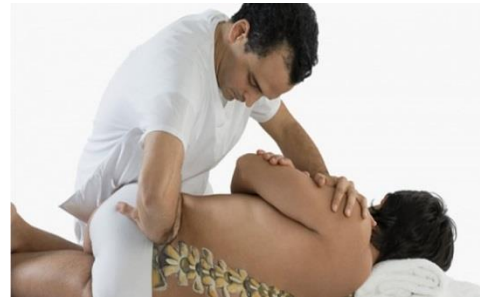Iliosacralgelenk

Therapie

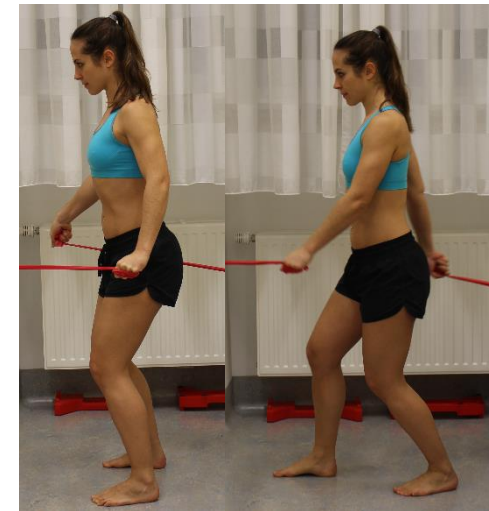
Infiltration



Manuelle Medizin



Physiotherapie



Einführung

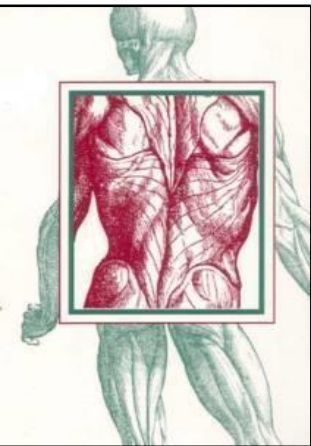
ISG

Facetten

Discus

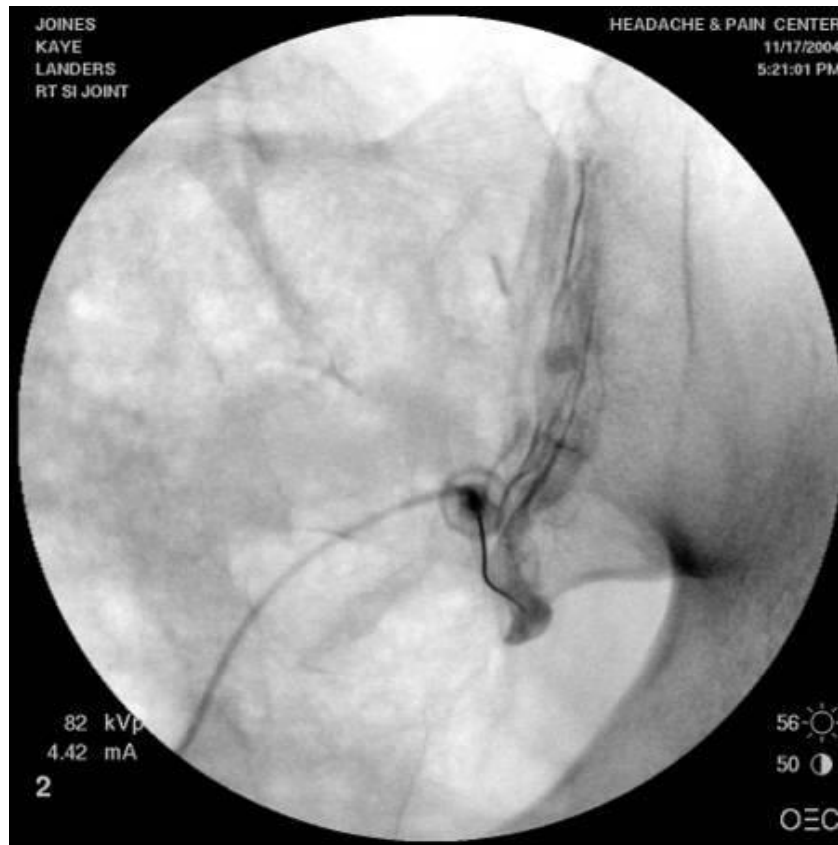
Piriformis

Take Home



Iliosacralgelenk

Röntgen gezielte Infiltration



Einführung

ISG

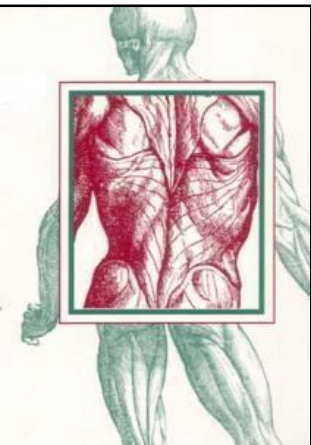
Facetten

Discus

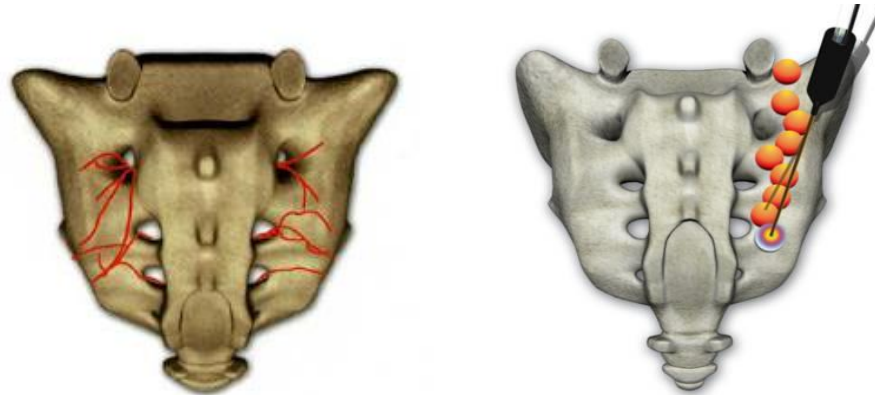
Piriformis

Take Home

Spezifischer Kreuzschmerzen



Radiofrequenztherapie (RF) des Iliosacralgelenkes (ISG)



[Stelzer W](#)¹, [Aiglesberger M](#), [Stelzer D](#), [Stelzer V](#).

Use of cooled radiofrequency lateral branch neurotomy for the treatment of sacroiliac joint-mediated low back pain: a large case series. [Pain Med](#). 2013 Jan;14(1):29-35.

Einführung

ISG

Facetten

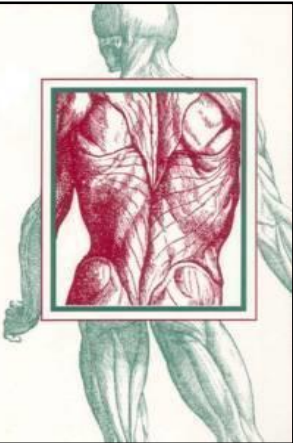
Discus

Piriformis

Take Home

Spezifischer Kreuzschmerzen

Radiofrequenztherapie (RF) des Iliosacralgelenkes (ISG)



Einführung

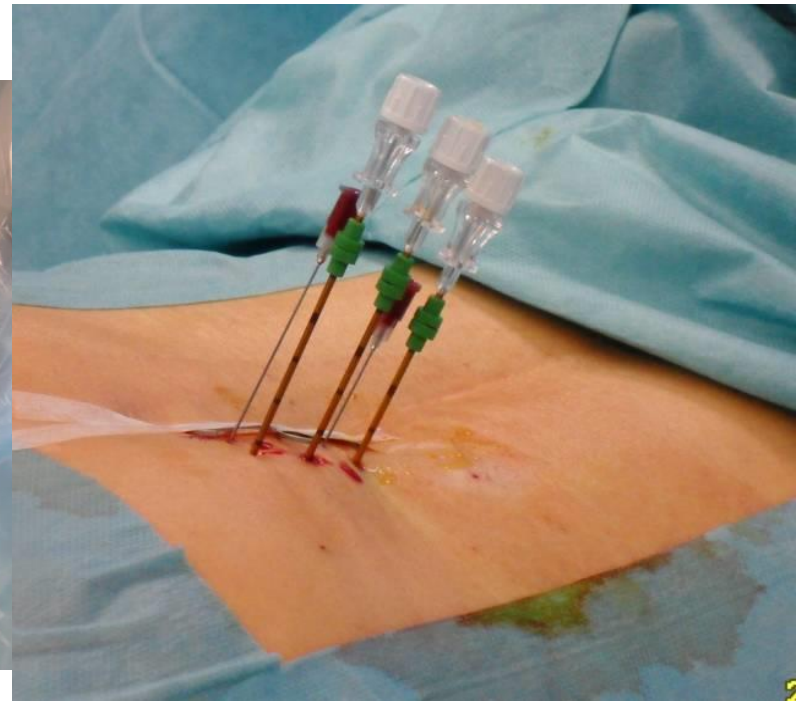
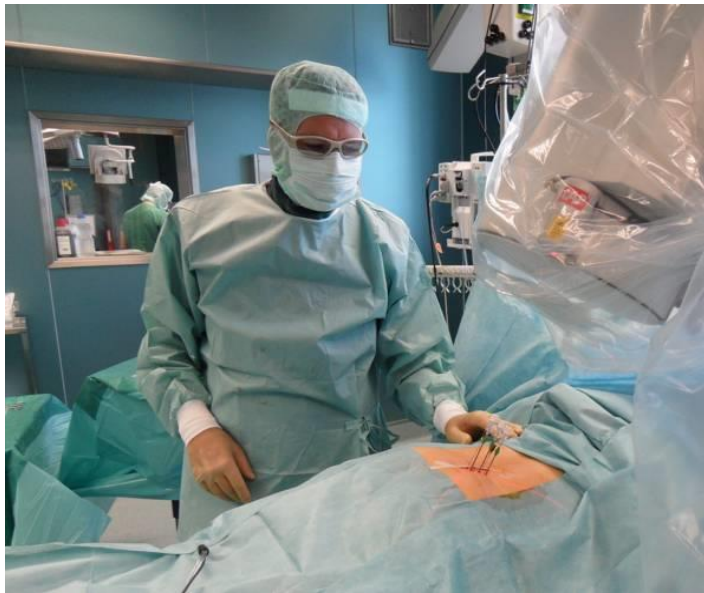ISG

Facetten

Discus

Piriformis

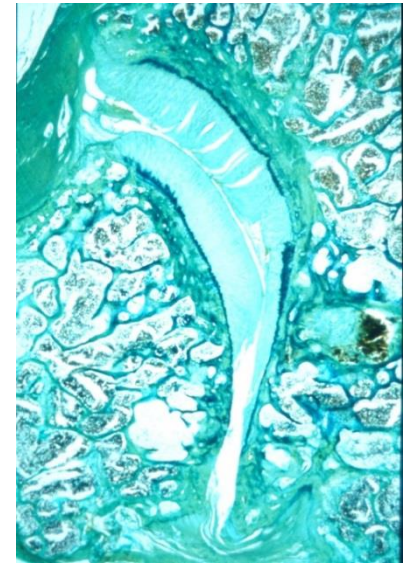
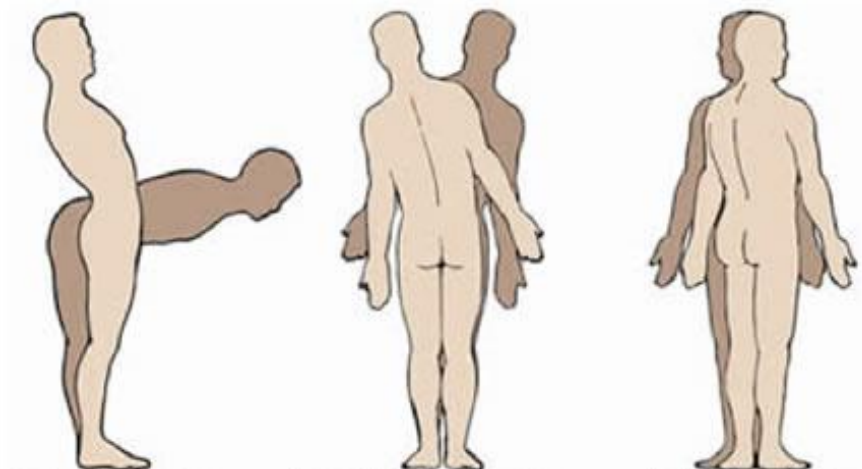
Take Home



Facettensyndrom

Klinik

In 1 Dimension in der Regel NICHT auslösbar (?)



Adams et al. (2013). The Biomechanics of Back Pain.

Einführung

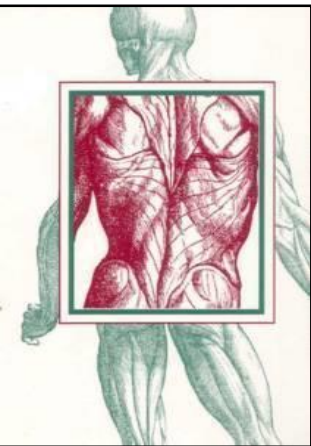
ISG

Facetten

Discus

Piriformis

Take Home



Facettensyndrom

Klinik

Einführung

ISG

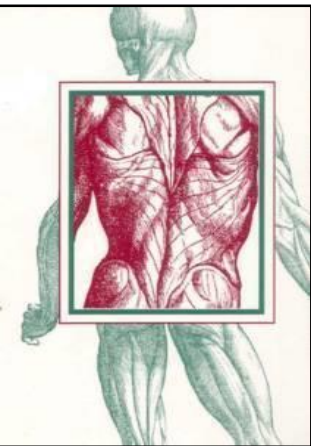
Facetten

Discus

Piriformis

Take Home

Spezifischer Kreuzschmerzen



Facettensyndrom

Klinik



?

Einführung

ISG

Facetten

Discus

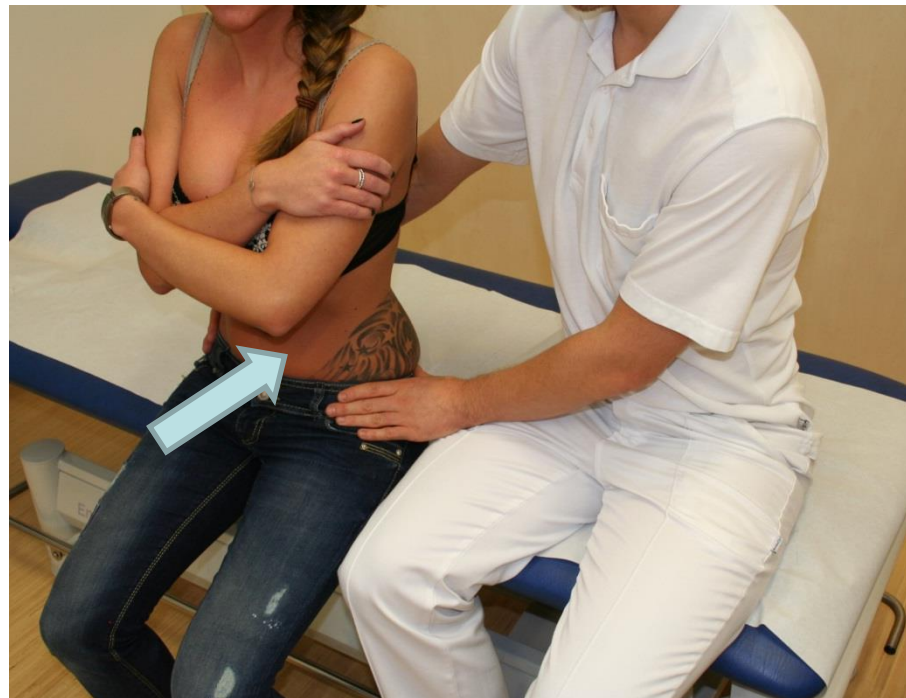Piriformis

Take Home

Spezifischer Kreuzschmerzen

Facettensyndrom

Klinik



Einführung

ISG

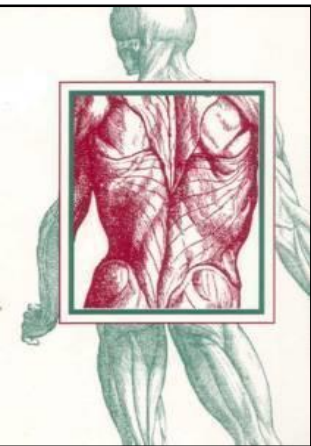
Facetten

Discus

Piriformis

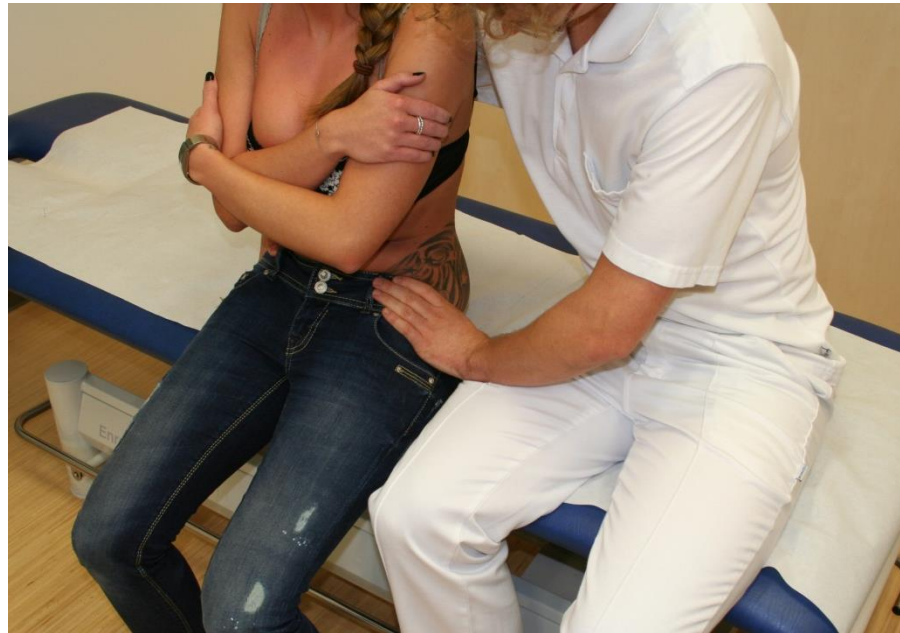Take Home

Spezifischer Kreuzschmerzen



Facettensyndrom

Klinik



Flexion



Einführung

ISG

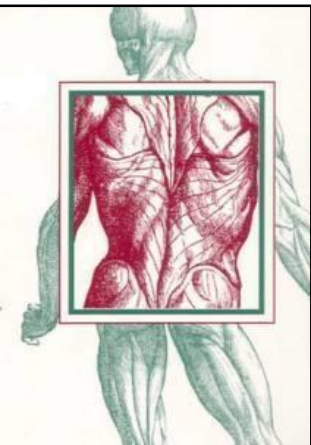
Facetten

Discus

Piriformis

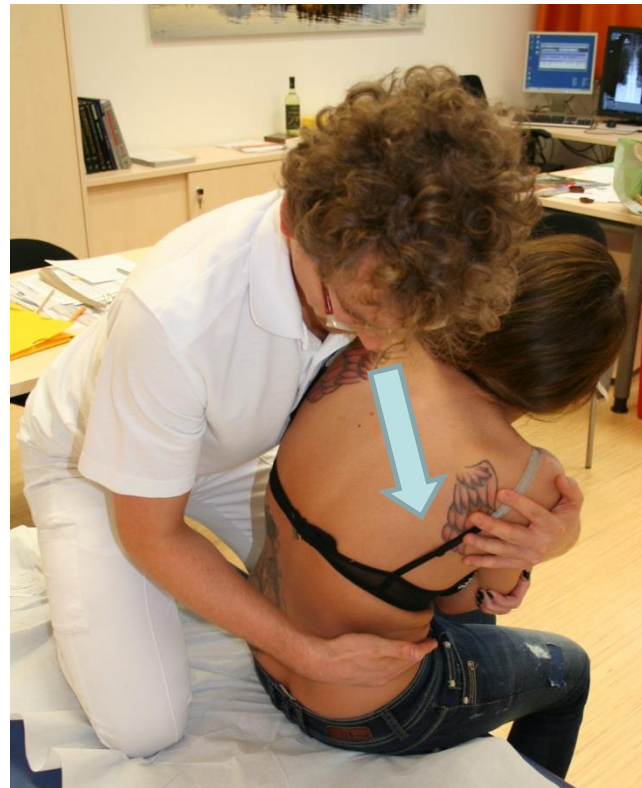
Take Home

Spezifischer Kreuzschmerzen



Facettensyndrom

Klinik



Seitneigung



Einführung

ISG

Facetten

Discus

Piriformis

Take Home

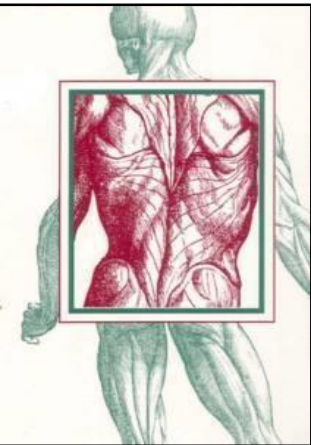
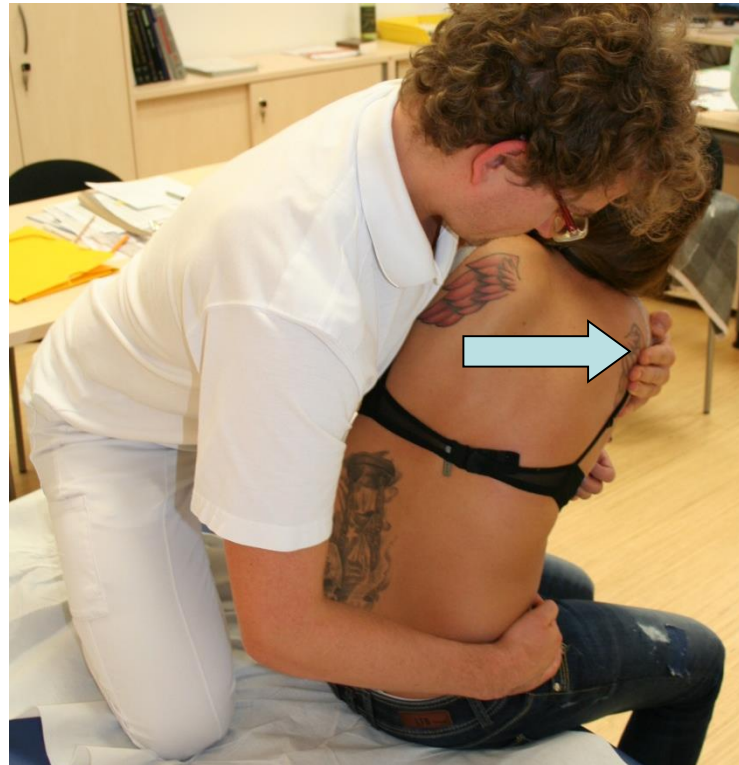
Spezifischer Kreuzschmerzen

Facettensyndrom

Klinik



Rotation



Einführung

ISG

Facetten

Discus

Piriformis

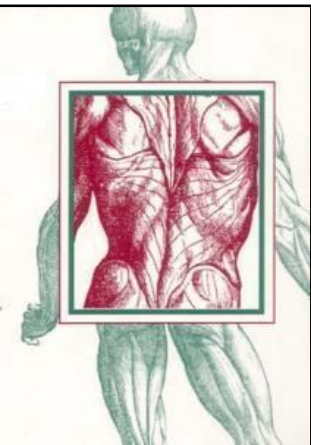
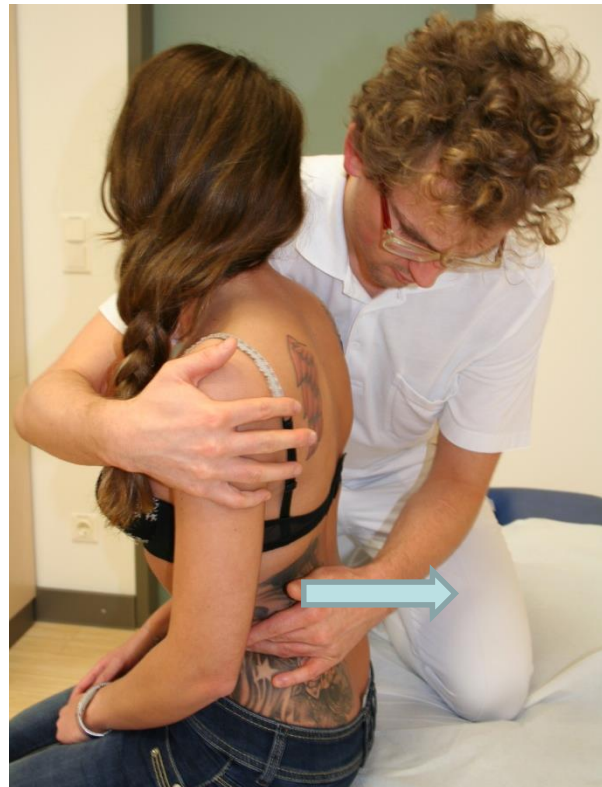Take Home

Facettensyndrom

Klinik



Extension



Einführung

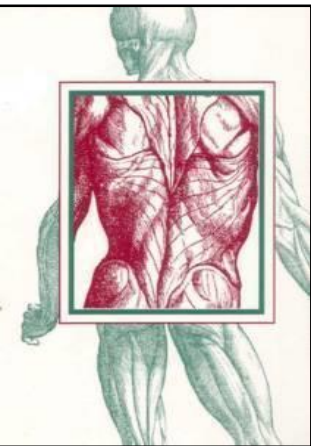
ISG

Facetten

Discus

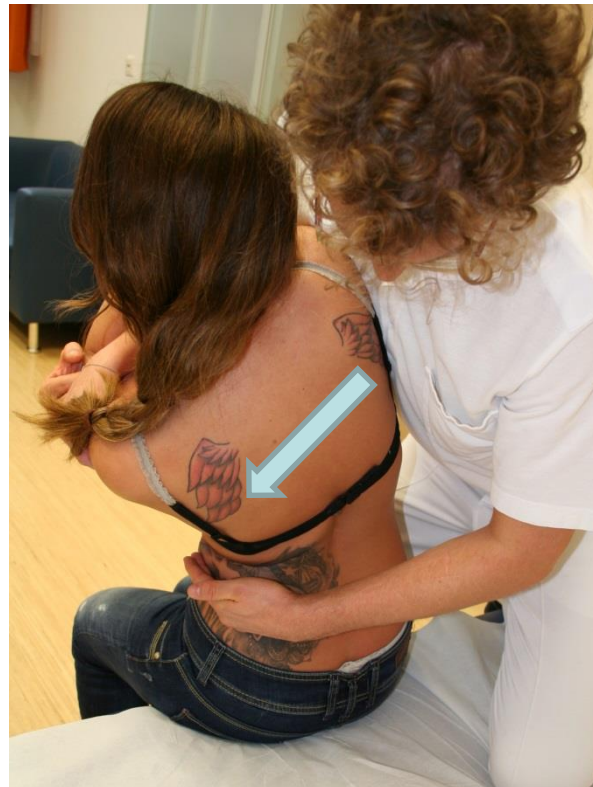
Piriformis

Take Home



Facettensyndrom

Klinik



Seitneigung



Einführung

ISG

Facetten

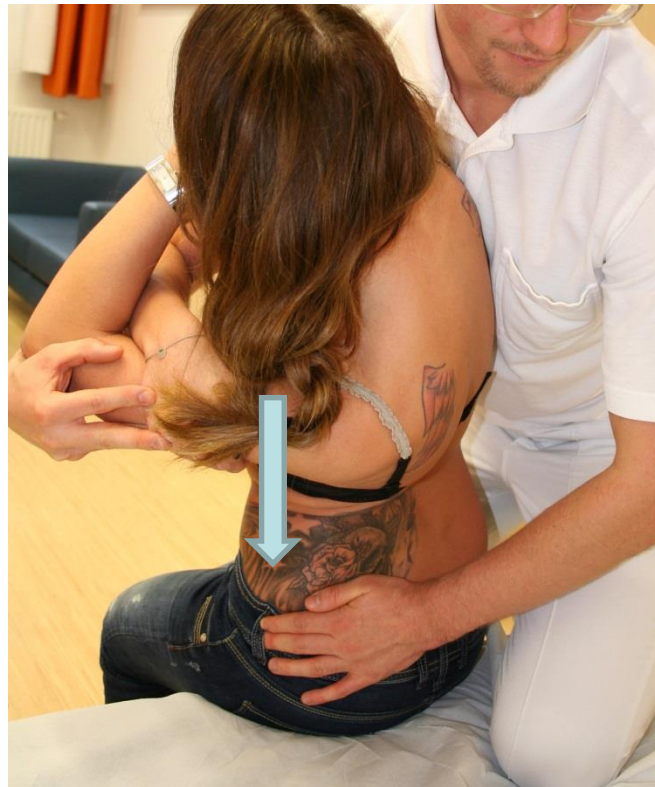
Discus

Piriformis

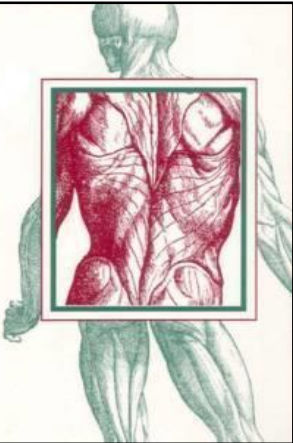
Take Home

Facettensyndrom

Klinik



Rotation



Einführung

ISG

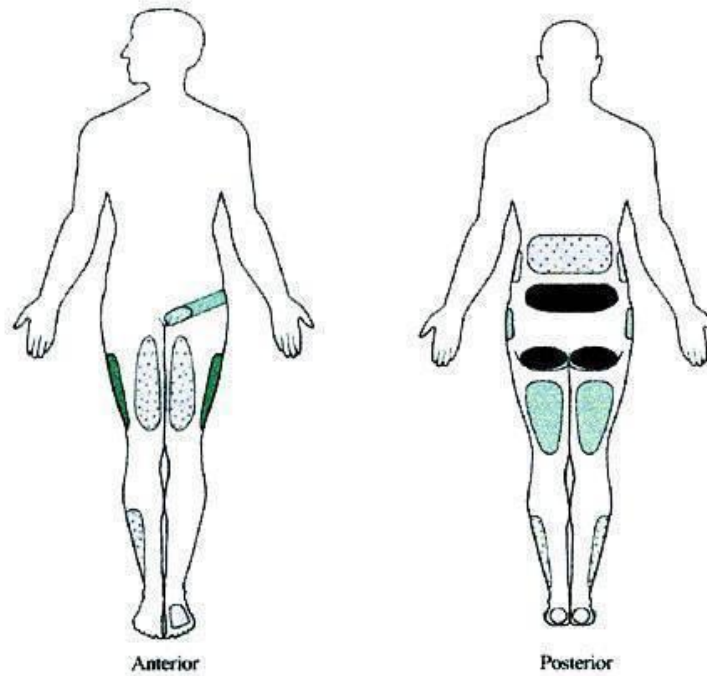
Facetten

Discus

Piriformis

Take Home

Facettensyndrom



Zusammenfassung von 17 Arbeiten über
Schmerzausstrahlung bei lumbal facet joint pain
[Cohen & Raja. Anesthesiology 2007; 106: 591-614](#)

Einführung

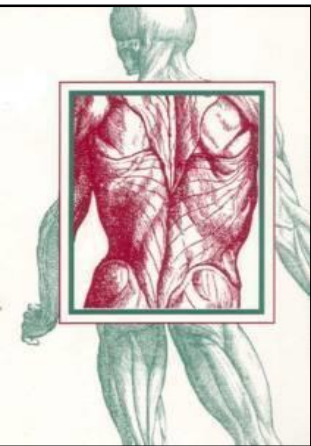
ISG

Facetten

Discus

Piriformis

Take Home



Facettengelenke

Therapie

Einführung

ISG

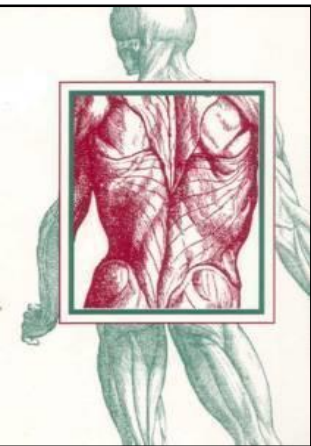
Facetten

Discus

Piriformis

Take Home

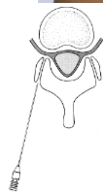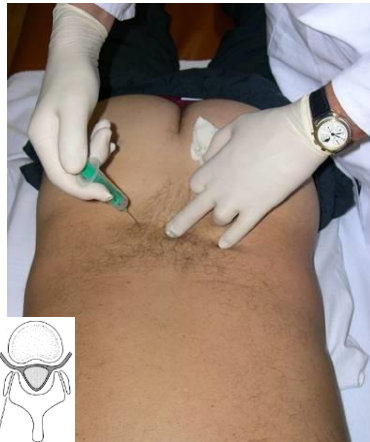Spezifischer Kreuzschmerzen



Facettengelenke

Therapie

Infiltration



Einführung

ISG

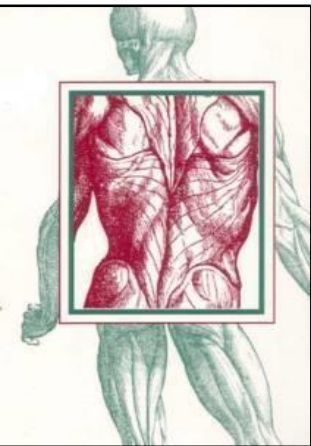
Facetten

Discus

Piriformis

Take Home

Spezifischer Kreuzschmerzen

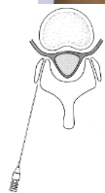
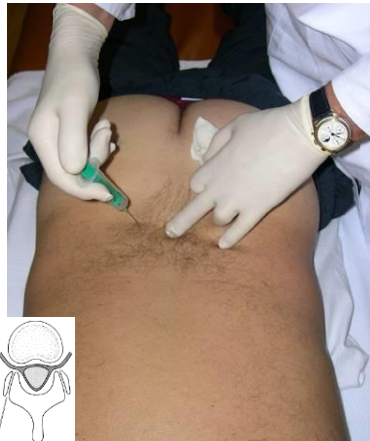
Facettengelenke

Therapie

Infiltration

Manuelle Medizin



Einführung

ISG

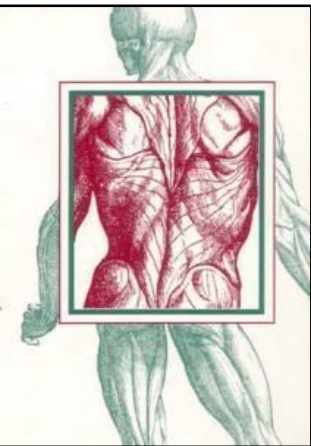
Facetten

Discus

Piriformis

Take Home

Spezifischer Kreuzschmerzen



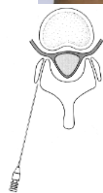
Facettengelenke

Therapie

Infiltration

Manuelle Medizin

Physiotherapie



Einführung

ISG

Facetten

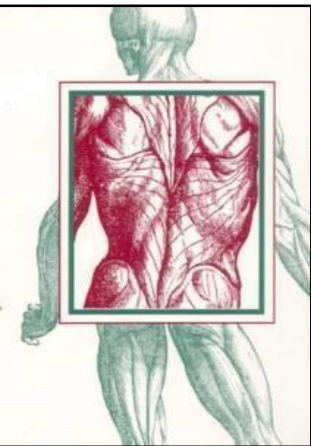
Discus

Piriformis

Take Home

Facettengelenke

Röntgen gezielte Infiltration (therapeutisch)



Einführung

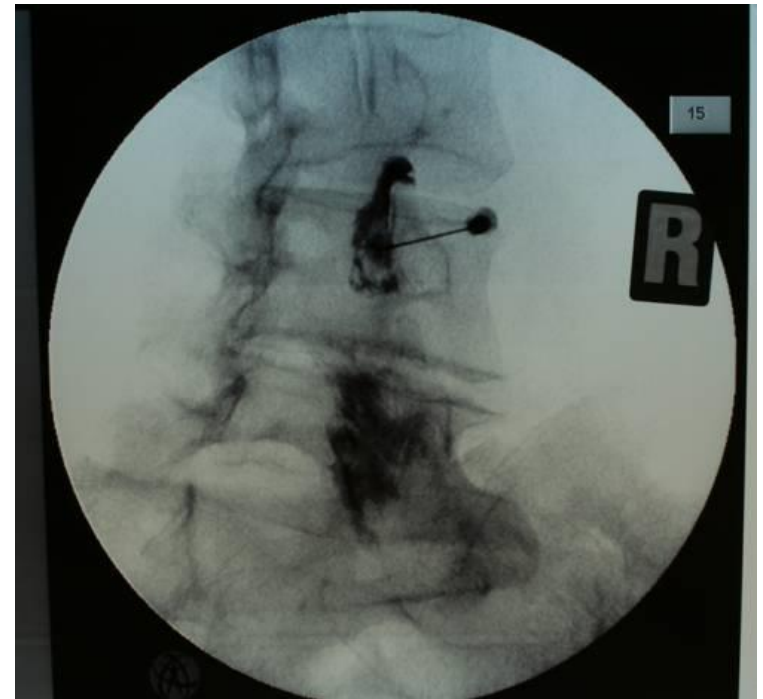
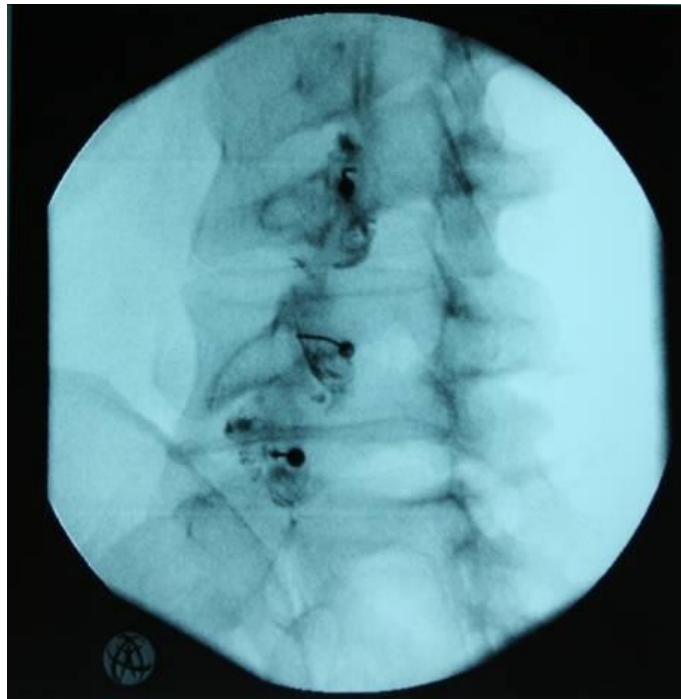
ISG

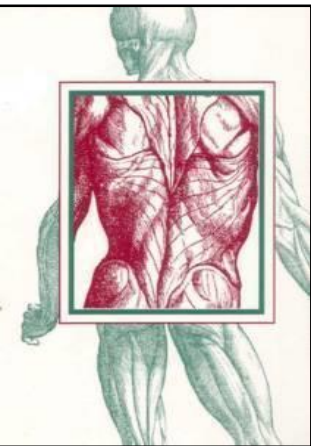
Facetten

Discus

Piriformis

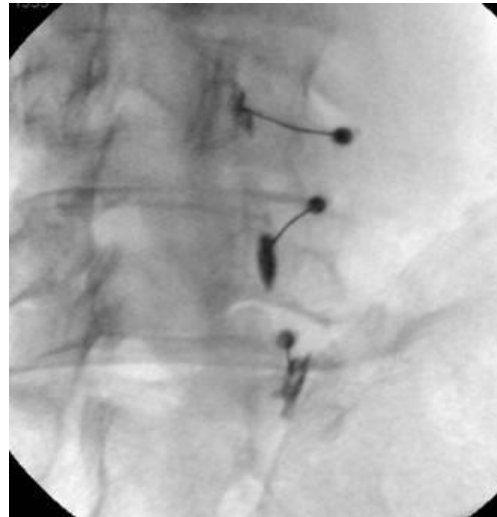Take Home





Radiofrequenztherapie (RF) der Facettengelenke

Voraussetzung: positive Testung mittels
R. medialis Blockade



Bei einer **Schmerzreduktion von > 50 %** besteht
die Indikation zur RF Therapie

Einführung

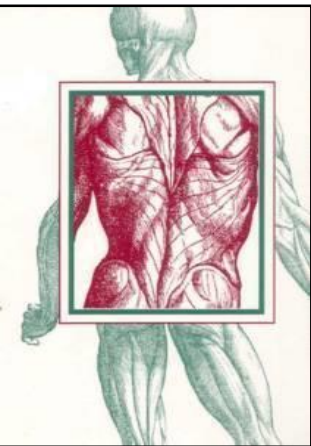
ISG

Facetten

Discus

Piriformis

Take Home



Radiofrequenztherapie (RF) der Facettengelenke

= eine durch Hitze verursachte (reversible)
Nervenläsion der Rr. mediales

RF ist eine kontinuierlich angewandte Hochfrequenztechnik
(Frequenz 300 kHz bis 2 MHz):

- starkes elektrisches und schwaches magnetisches Feld
- dadurch induzierte Temperaturerhöhung

- **80 Grad Celcius**
- **90 Sekunden pro Läsion**



Einführung

ISG

Facetten

Discus

Piriformis

Take Home

Facettensyndrom

The lumbar facet joint: a review of current knowledge: part 1: anatomy, biomechanics, and grading.

[Varlotta GP](#), [Lefkowitz TR](#), [Schweitzer M](#), [Errico TJ](#), [Spivak J](#), [Bendo JA](#), [Rybak L](#). Skeletal Radiol. 2010 Jul 13. [Epub ahead of print]

The lumbar facet joint: a review of current knowledge: Part II: diagnosis and management.

[Varlotta GP](#), [Lefkowitz TR](#), [Schweitzer M](#), [Errico TJ](#), [Spivak J](#), [Bendo JA](#), [Rybak L](#). Skeletal Radiol. 2010 Jun 26. [Epub ahead of print]

Pain Originating from the Lumbar Facet Joints.

[van Kleef M](#), [Vanelderden P](#), [Cohen SP](#), [Lataster A](#), [Van Zundert J](#), [Mekhail N](#). Pain Pract. 2010 Jul 26

Multicenter, randomized, comparative cost-effectiveness study comparing 0, 1, and 2 diagnostic medial branch (facet joint nerve) block treatment paradigms before lumbar facet radiofrequency denervation.

[Cohen SP](#), [Williams KA](#), [Kurihara C](#), [Nguyen C](#), [Shields C](#), [Kim P](#), [Griffith SR](#), [Larkin TM](#), [Crooks M](#), [Williams N](#), [Morlando B](#), [Strassels SA](#). Anesthesiology. 2010 Aug;113(2):395-405.

Einführung

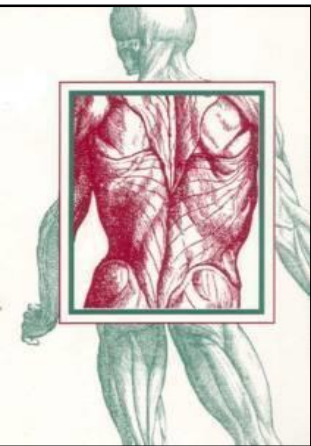
ISG

Facetten

Discus

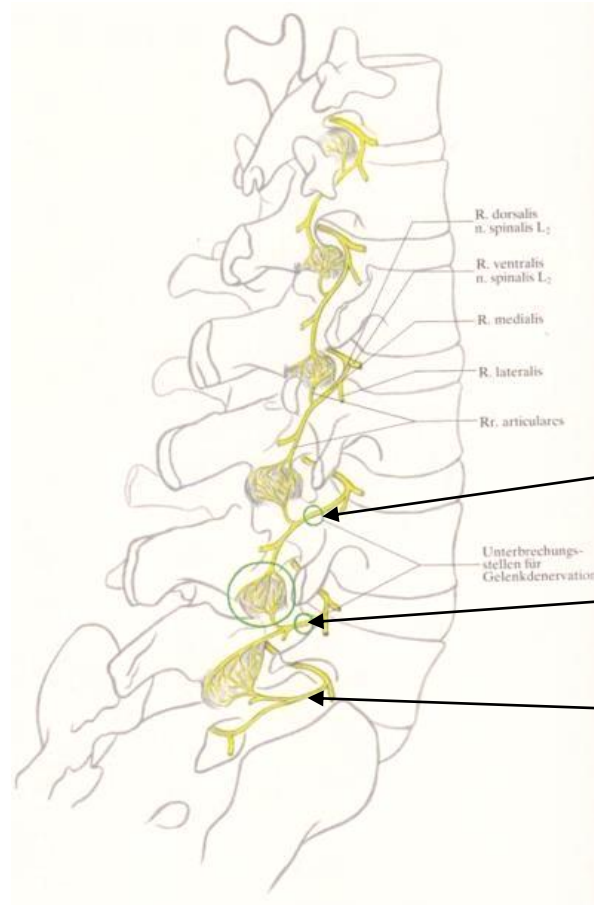
Piriformis

Take Home



- Einführung
- ISG
- Facetten**
- Discus
- Piriformis
- Take Home

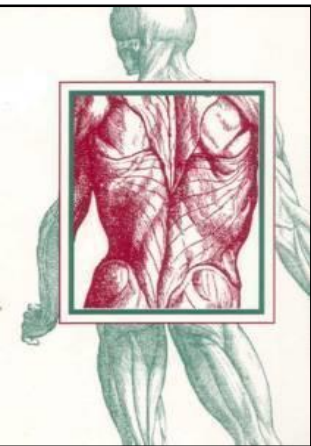
Radiofrequenztherapie (RF)



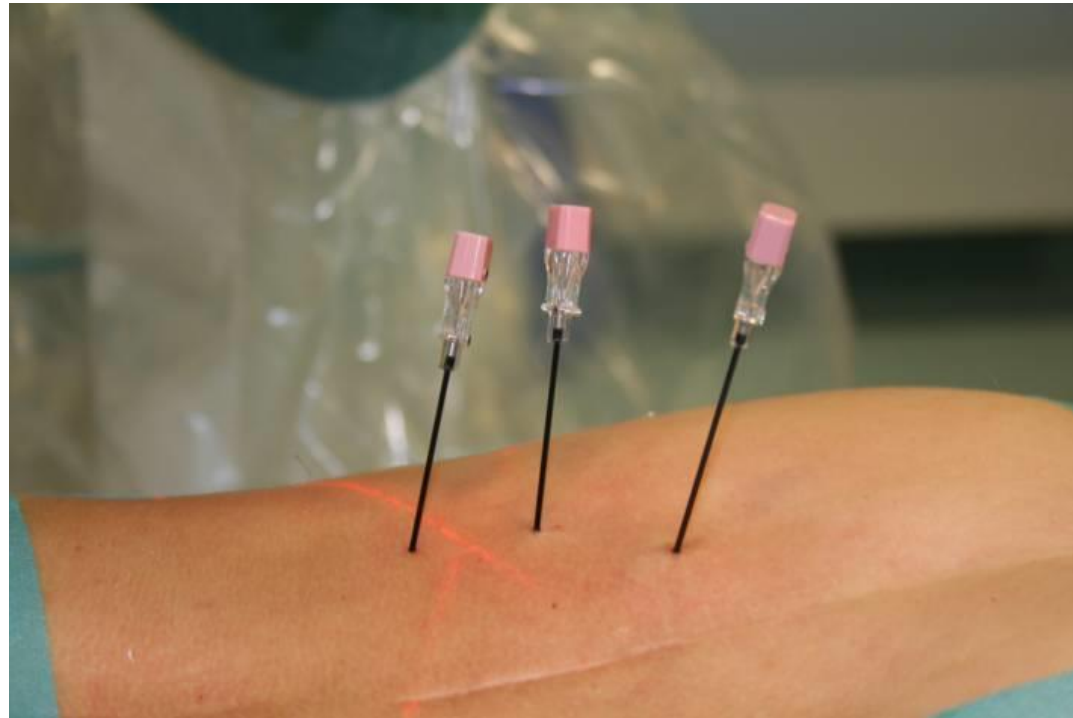
R. medialis L3

R. medialis L4

R. dorsalis L5



Radiofrequenztherapie (RF) der Facettengelenke



Einführung

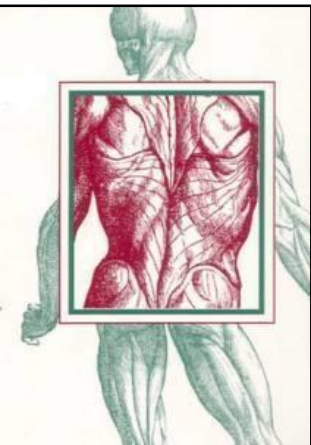
ISG

Facetten

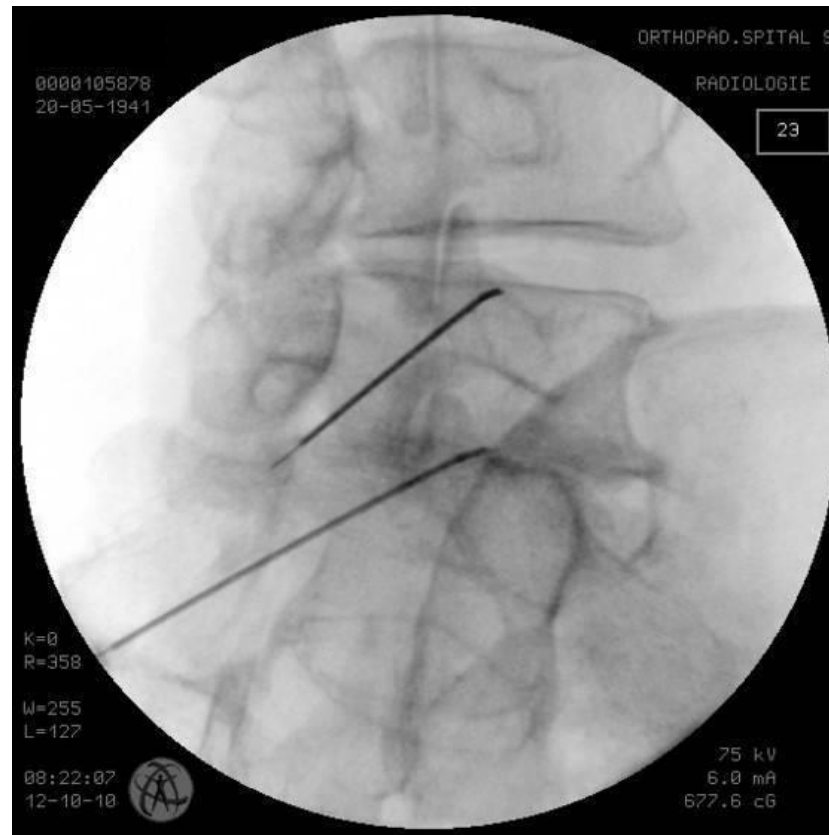Discus

Piriformis

Take Home



Radiofrequenztherapie (RF) der Facettengelenke



Einführung

ISG

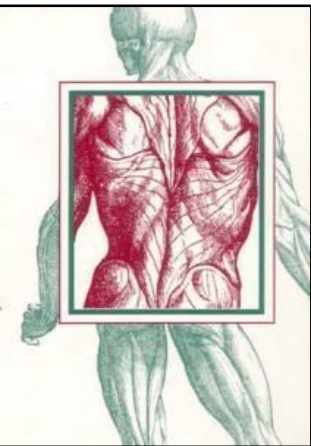
Facetten

Discus

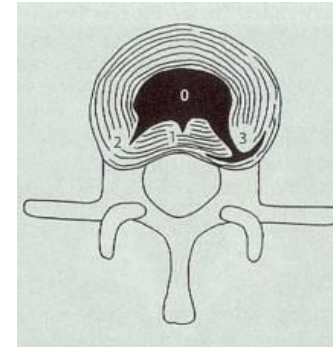
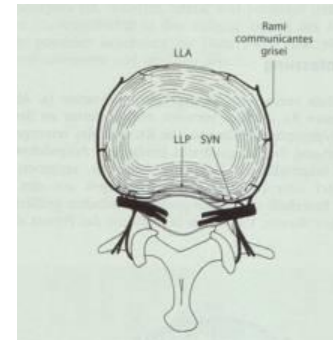
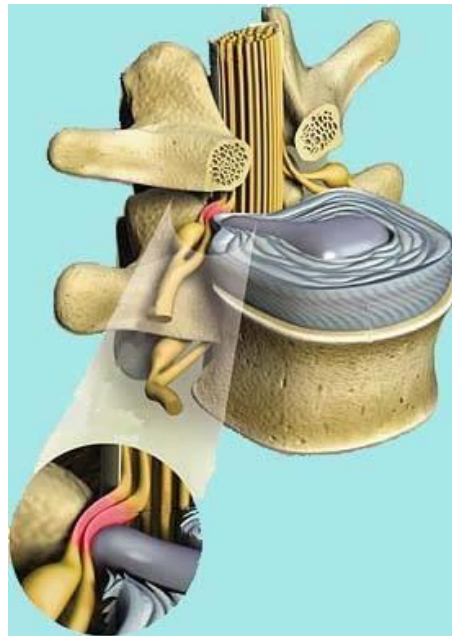Piriformis

Take Home

Spezifischer Kreuzschmerzen



Lumbaler Bandscheibenschaden (mit/ohne radikulärem Schmerzbild)



Einführung

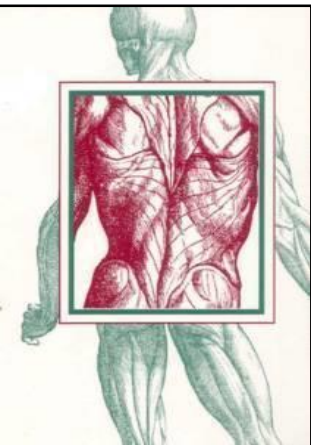
ISG

Facetten

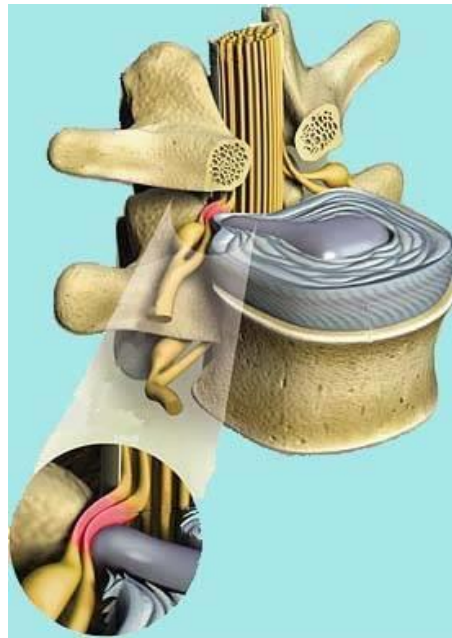Discus

Piriformis

Take Home



Lumbaler Bandscheibenschaden (mit radikulärem Schmerzbild)



- **Radix L4** (DP L4/5)
- **Radix L5**
(DP L4/5 oder L5/S1)
- **Radix S1** (DP L5/S1)

Einführung

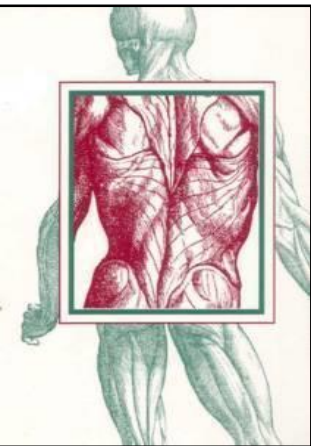
ISG

Facetten

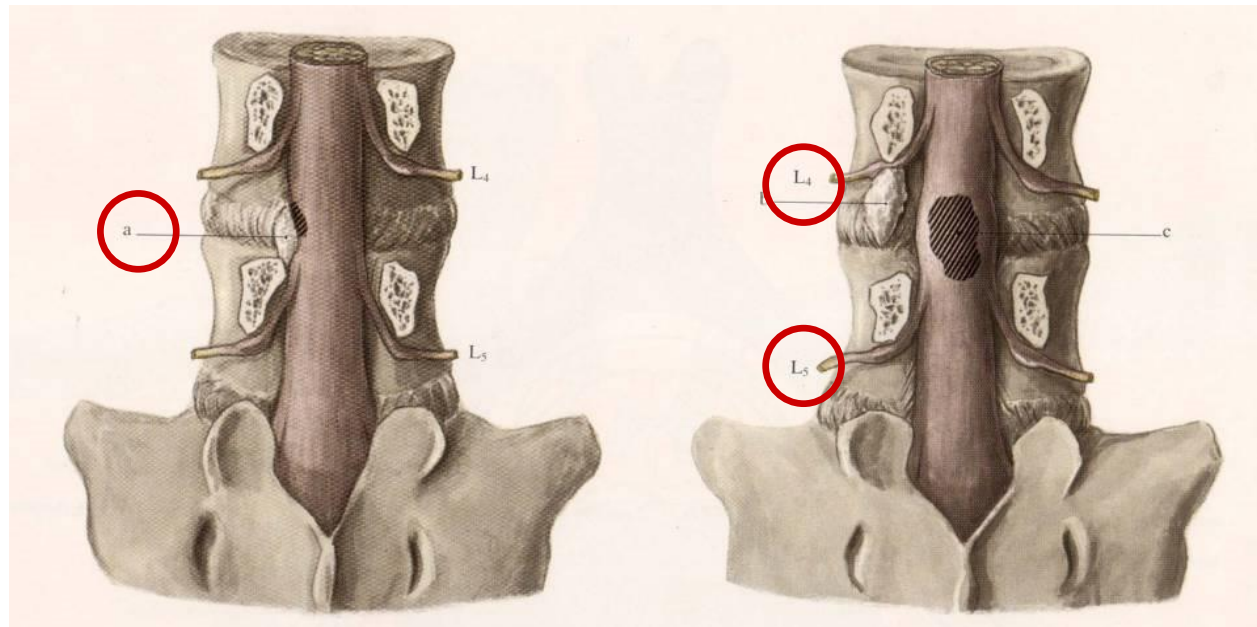
Discus

Piriformis

Take Home



Lumbaler Bandscheibenschaden (mit radikulärem Schmerzbild)



Einführung

ISG

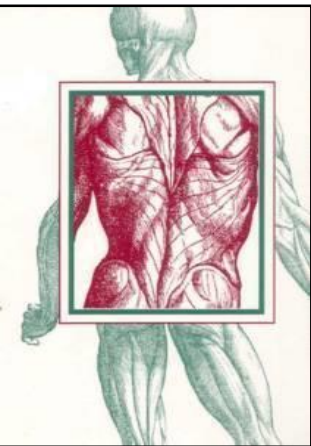
Facetten

Discus

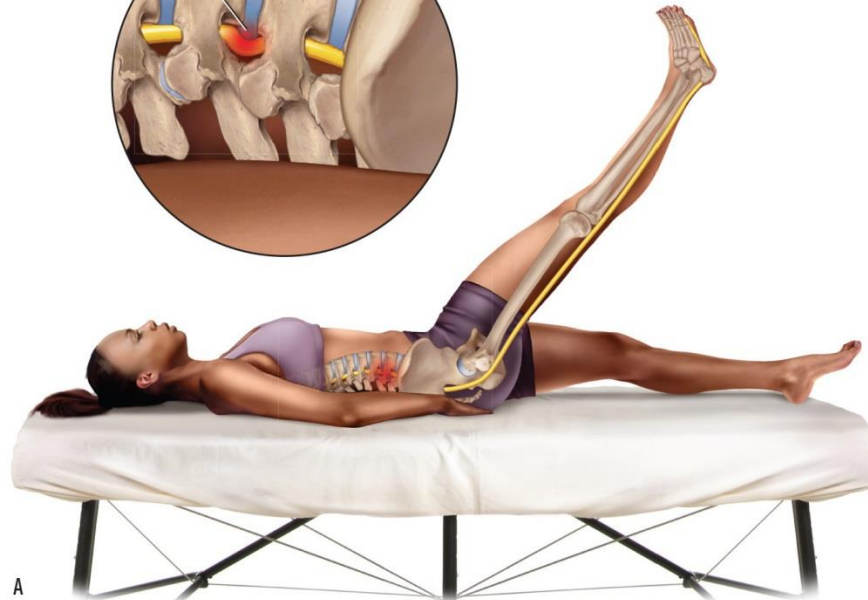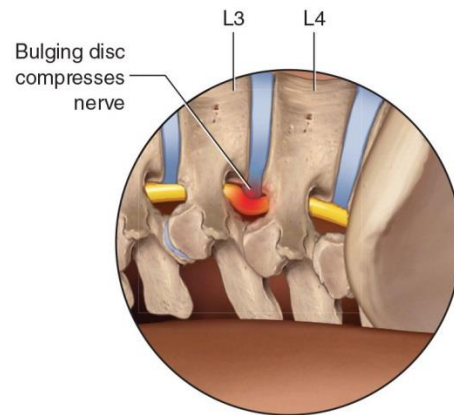
Piriformis

Take Home

Spezifischer Kreuzschmerzen



Klinik



A

Copyright © 2015 Wolters Kluwer Health | Lippincott Williams & Wilkins

Einführung

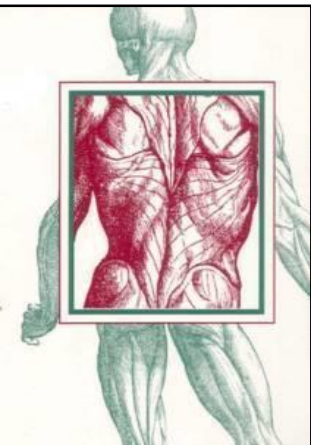
ISG

Facetten

Discus

Piriformis

Take Home



REFLEXE



Einführung

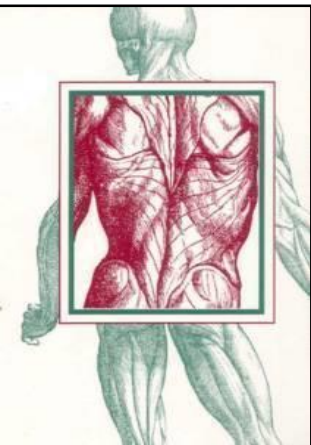
ISG

Facetten


Discus

Piriformis

Take Home



MOTORIK



Einführung

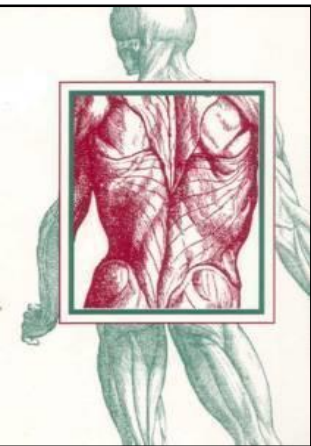
ISG

Facetten

Discus

Piriformis

Take Home



SENSIBILITÄT



Einführung

ISG

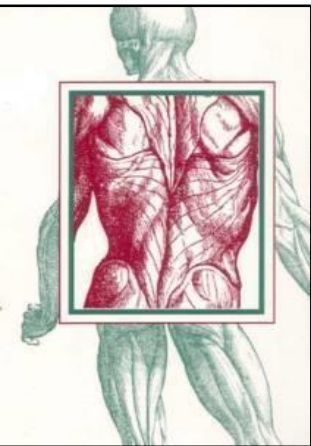
Facetten

Discus

Piriformis

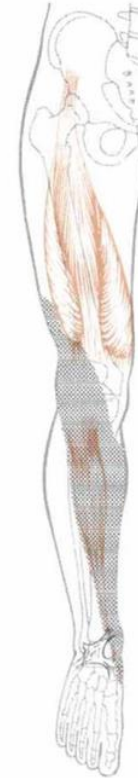Take Home

Spezifischer Kreuzschmerzen



L4

Segment	L 4
Dermatome	von der Außenseite des Oberschenkels bis zum inneren Unterschenkel und inneren Fußrand
Kennmuskeln	Parese des M. quadriceps femoris und M. tibialis anterior
Reflexausfälle	Abschwächung des PSR



Einführung

ISG

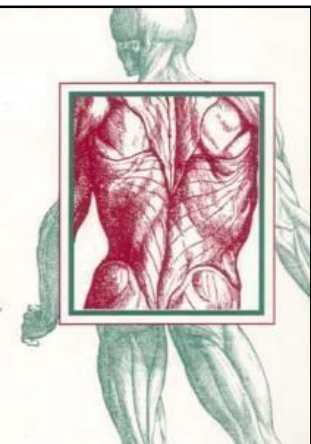Facetten

Discus

Piriformis

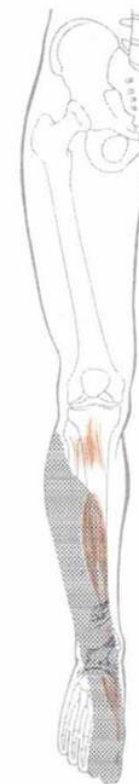Take Home

Spezifischer Kreuzschmerzen



L5

Segment	L 5
Dermatome	vom äußeren Unterschenkel bis zur Großzehe
Kennmuskeln	Parese des M. hallucis longus; Fersengang gestört
Reflexausfälle	Ausfall des Tibialis-posterior-Reflexes (unsicher)



Einführung

ISG

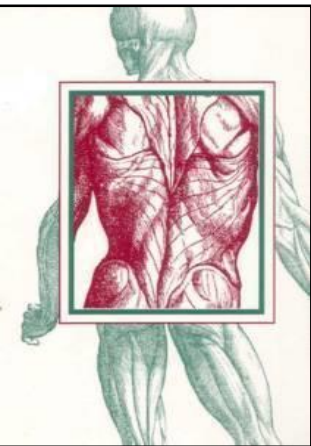
Facetten

Discus

Piriformis

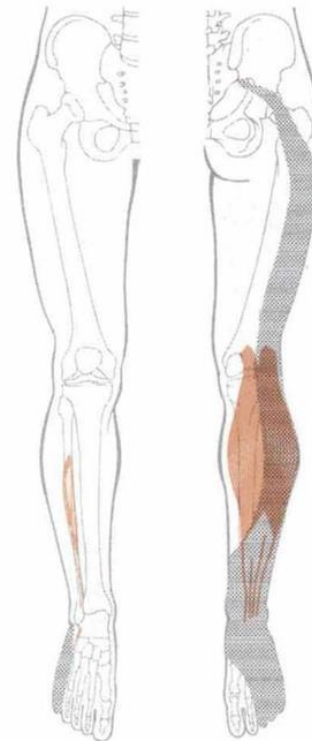
Take Home

Spezifischer Kreuzschmerzen



S1

Segment	S 1
Dermatome	Rückseite von Ober- und Unterschenkel bis zur Kleinzehne
Kennmuskeln	Parese der Mm. peronaei und des M. triceps surae; Zehengang gestört
Reflexausfälle	Ausfall des Achillessehnenreflexes (ASR)



Einführung

ISG

Facetten

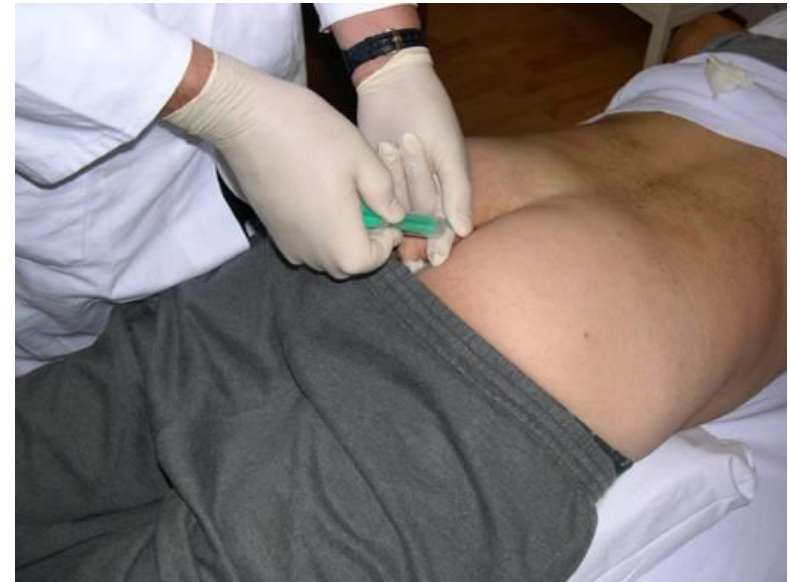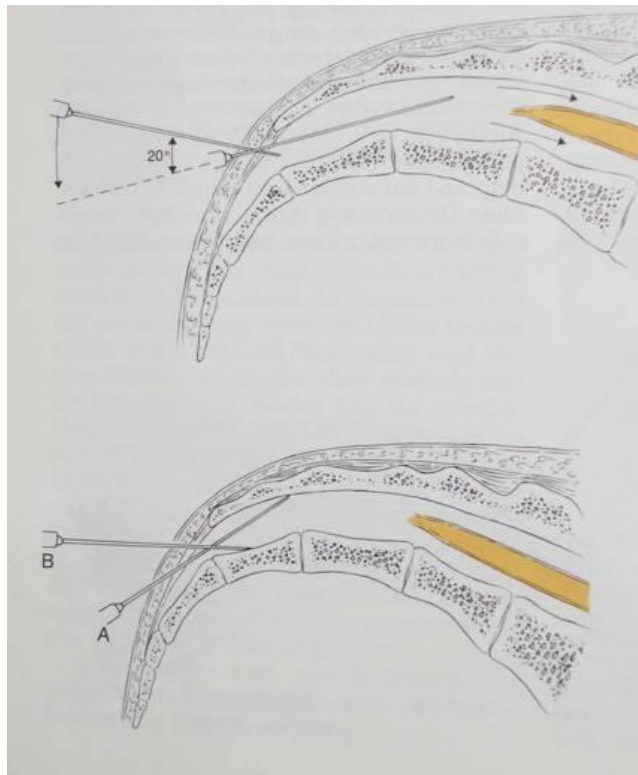
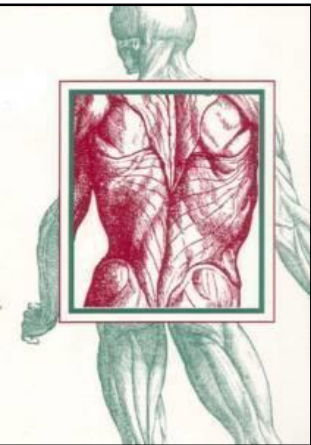
Discus

Piriformis

Take Home

Spezifischer Kreuzschmerzen

Sacrale Überflutung



Einführung

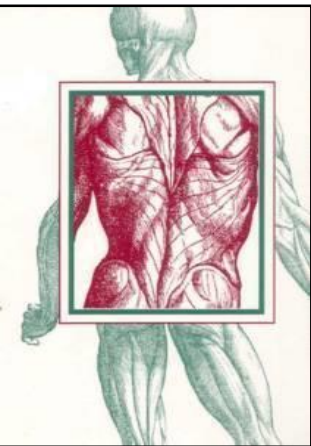
ISG

Facetten

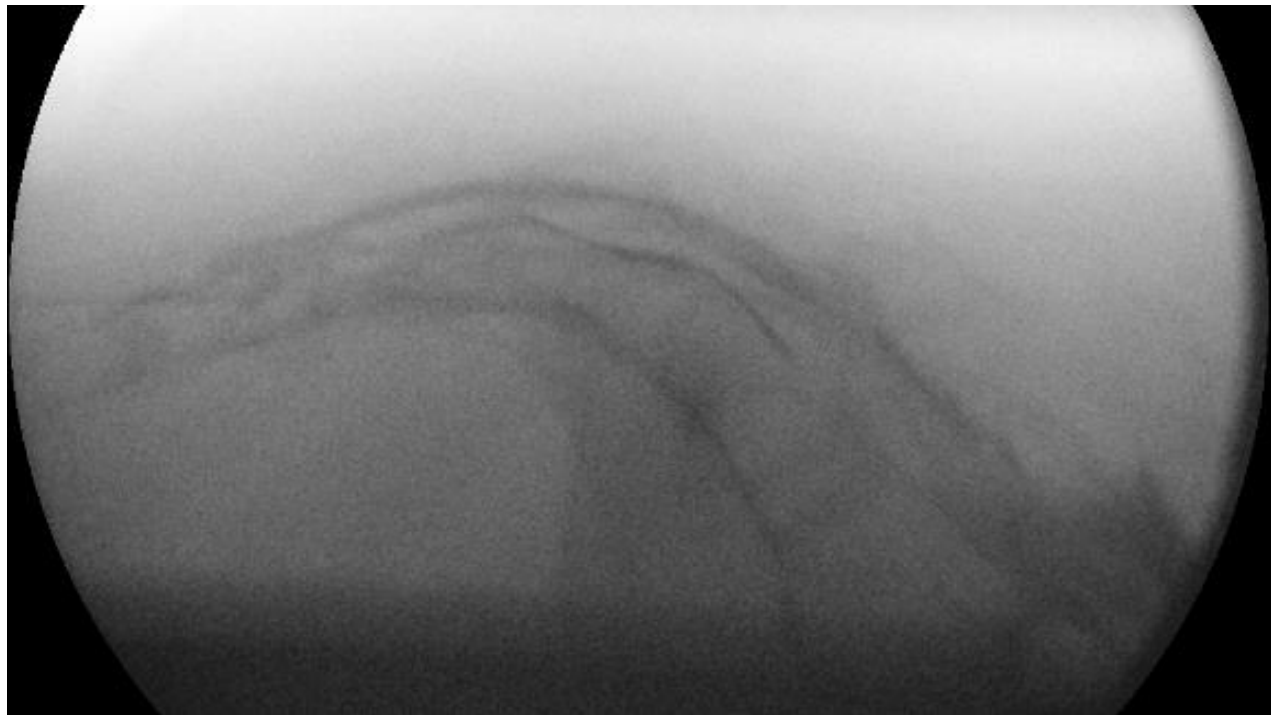
Discus

Piriformis

Take Home



Sacrale Überflutung



Einführung

ISG

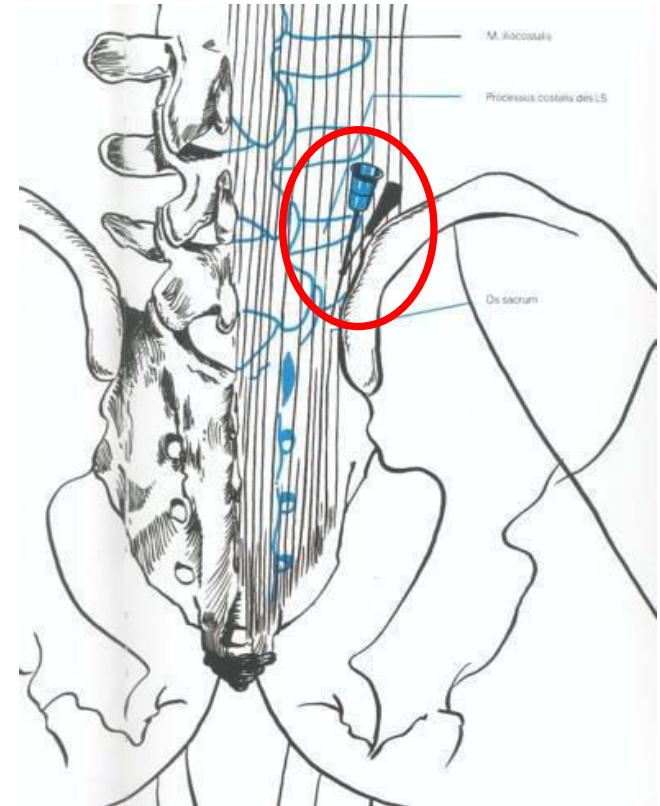
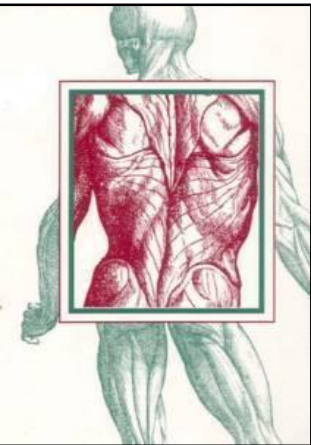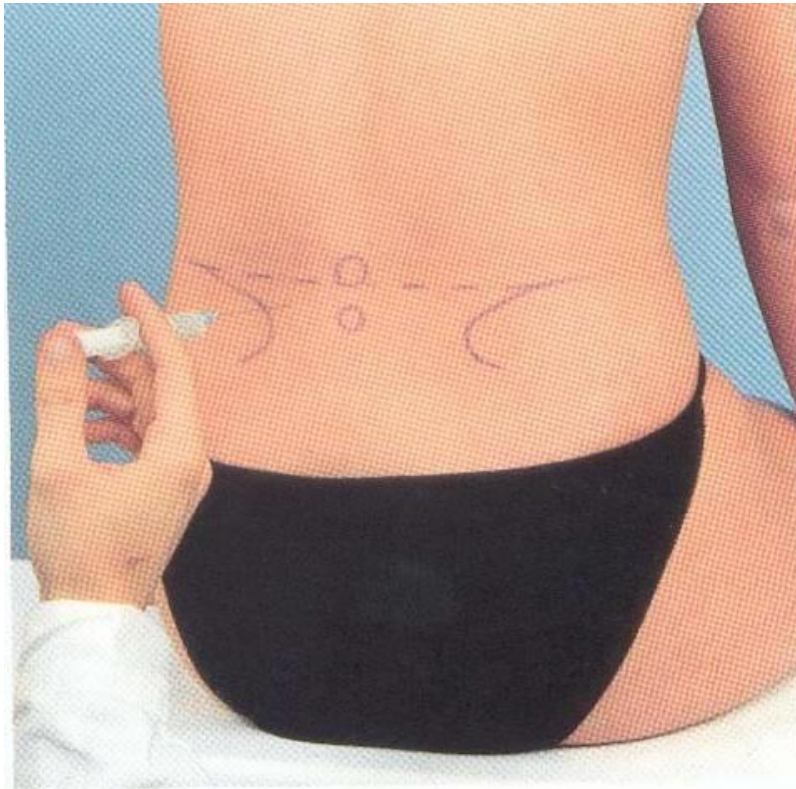
Facetten

Discus

Piriformis

Take Home

Reischauer Blockade



Einführung

ISG

Facetten

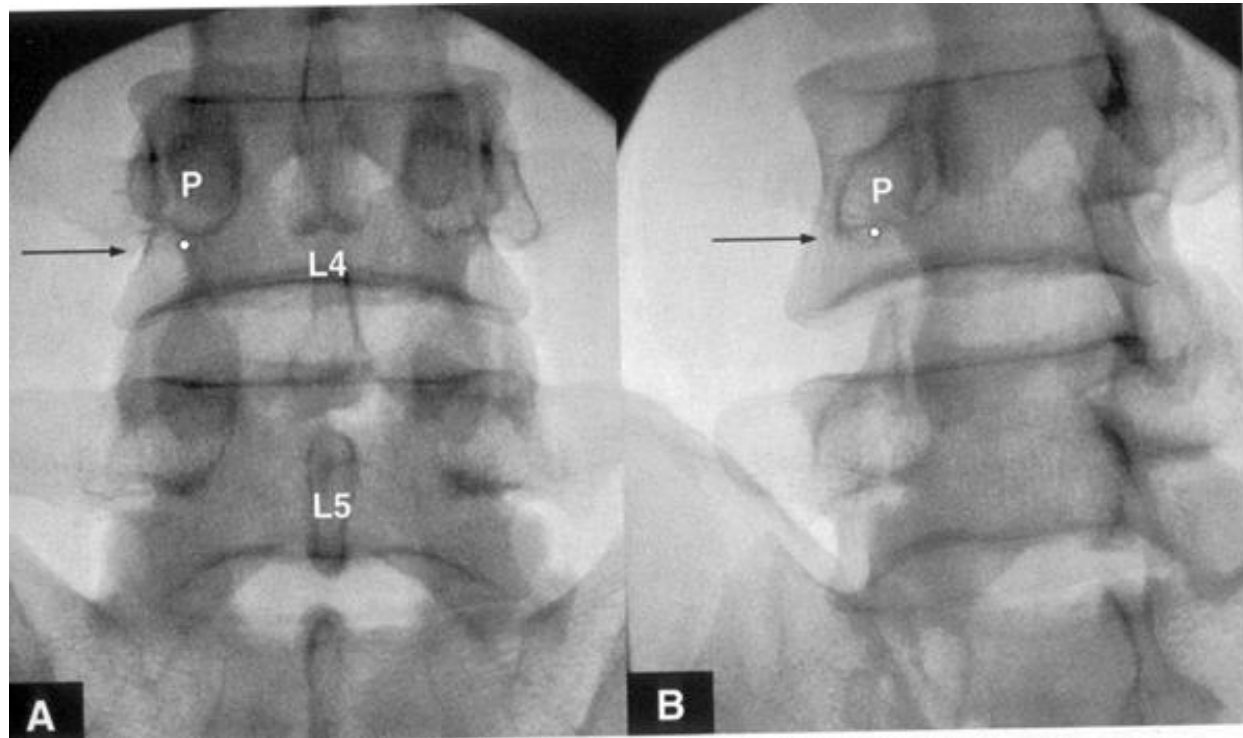
Discus

Piriformis

Take Home

Spezifischer Kreuzschmerzen

Transforaminale epidurale Infiltration



Einführung

ISG

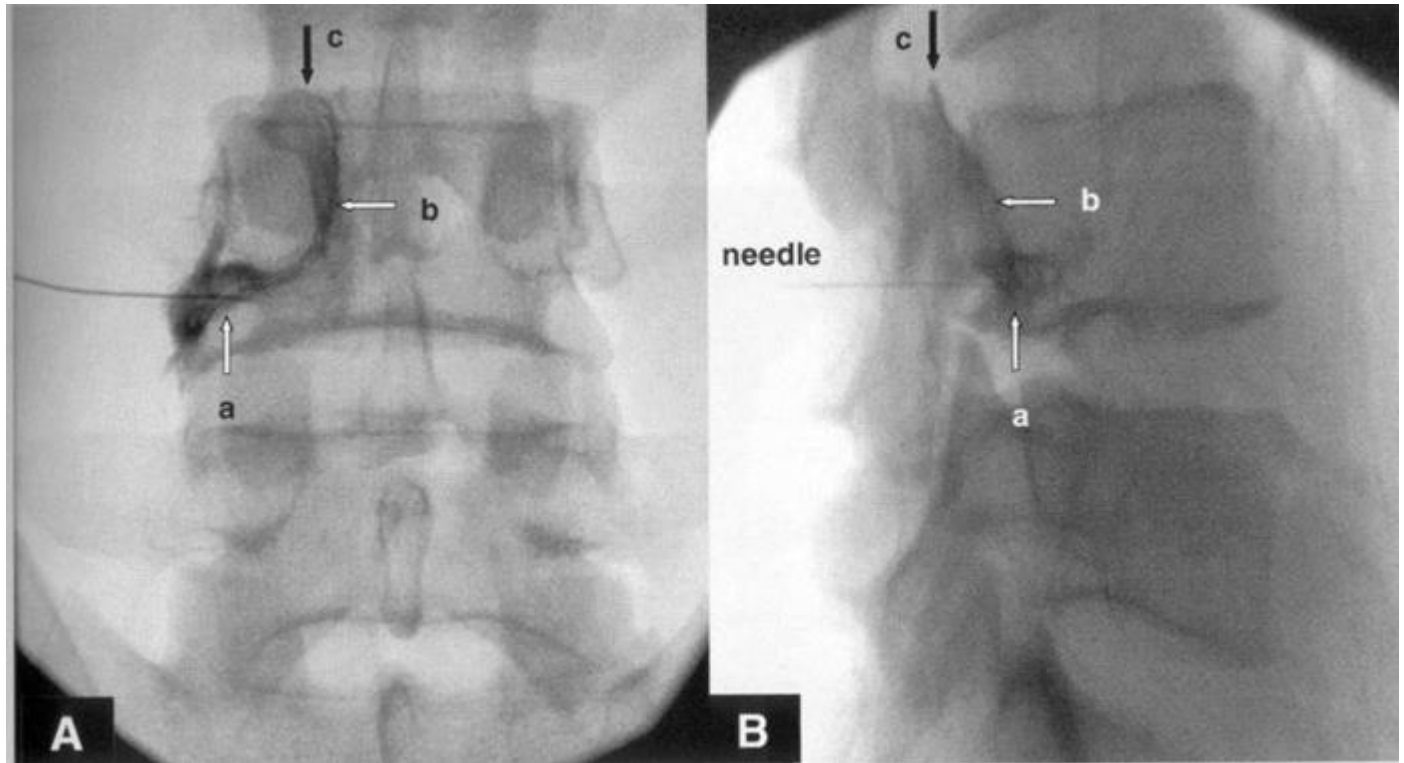
Facetten

Discus

Piriformis

Take Home

Transforaminale epidurale Infiltration



Einführung

ISG

Facetten

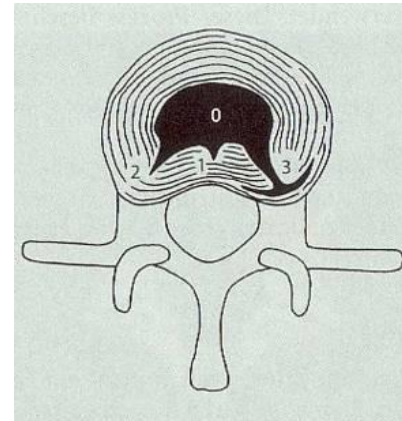
Discus

Piriformis

Take Home

Discogener Schmerz

- **Diszitis**
- **Torsionsverletzung**
- **Innere Diskusruptur :**
 - 3 Grade
 - positiv, wenn die angrenzenden Bandscheiben den Schmerz nicht reproduzieren (!)



Einführung

ISG

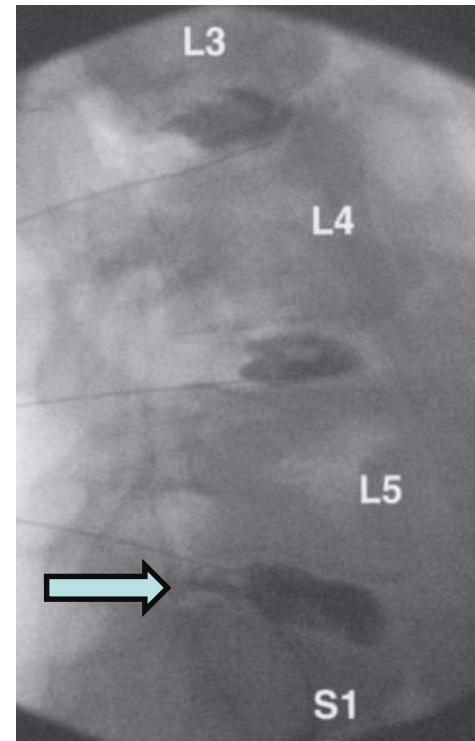
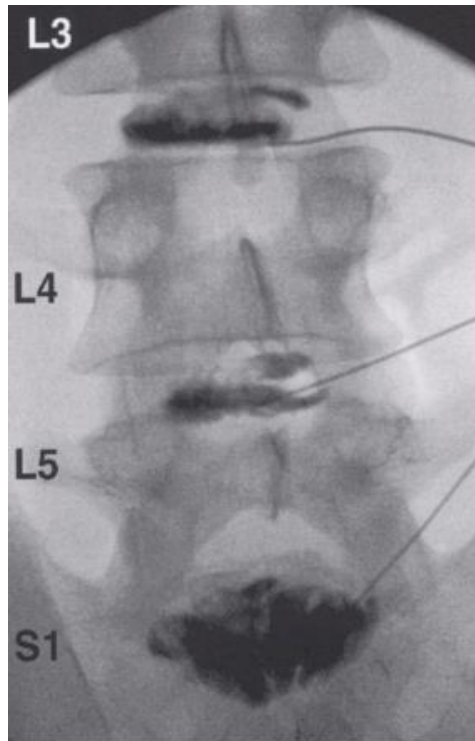
Facetten

Discus

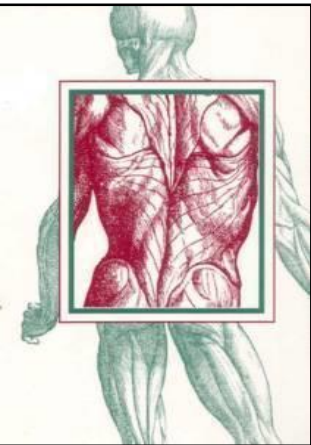
Piriformis

Take Home

Discogener Schmerz



Provokationsdiscographie
mit periduralem KM-Austritt bei L5/S1



Einführung

ISG

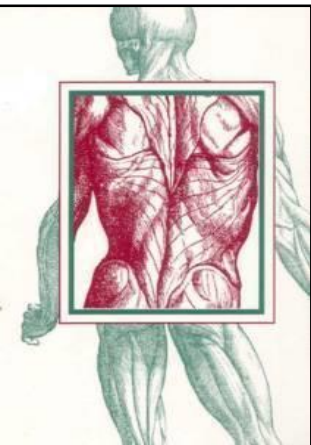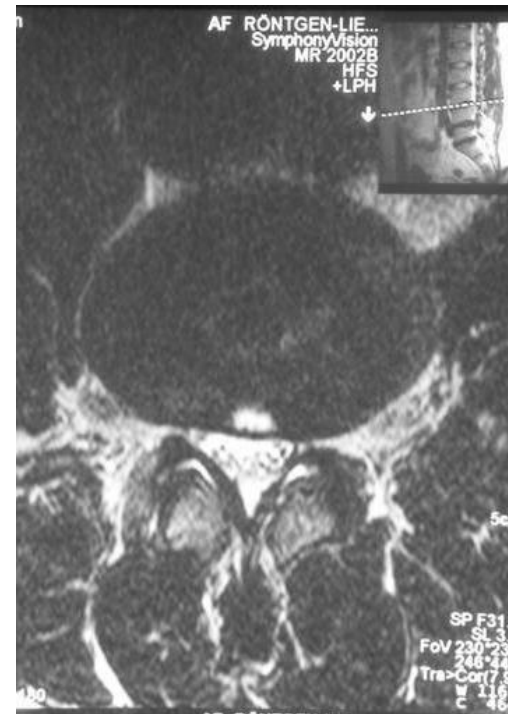
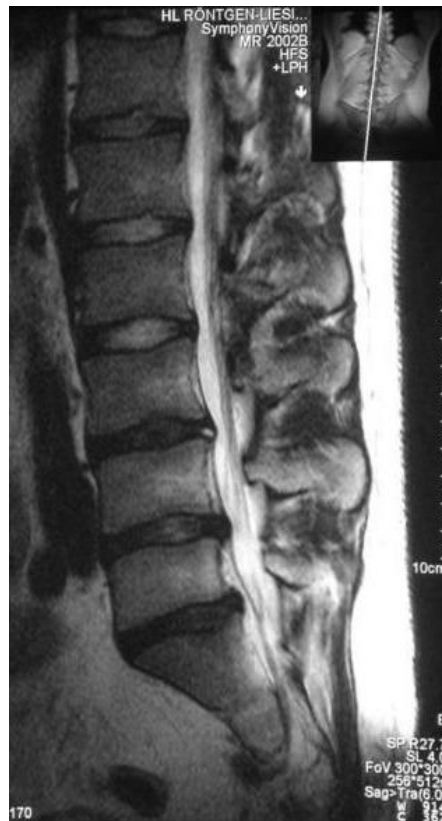Facetten

Discus

Piriformis

Take Home

Discogener Schmerz



Einführung

ISG

Facetten

Discus

Piriformis

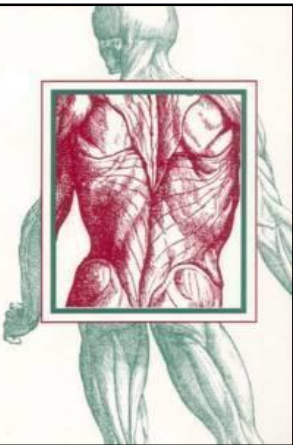
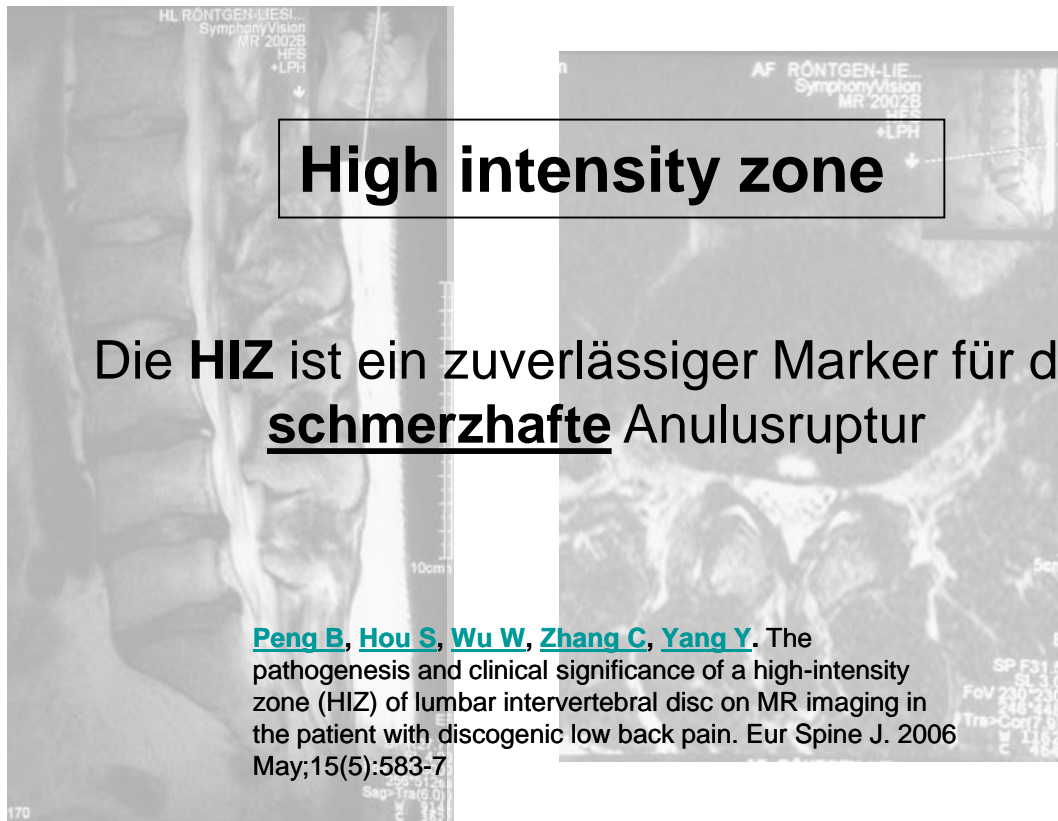Take Home

Discogener Schmerz

High intensity zone

Die **HIZ** ist ein zuverlässiger Marker für die schmerzhafte Anulusruptur

[Peng B](#), [Hou S](#), [Wu W](#), [Zhang C](#), [Yang Y](#). The pathogenesis and clinical significance of a high-intensity zone (HIZ) of lumbar intervertebral disc on MR imaging in the patient with discogenic low back pain. Eur Spine J. 2006 May;15(5):583-7



Einführung

ISG

Facetten

Discus

Piriformis

Take Home

Discogener Schmerz

„ständige tiefe Schmerzen, die durch die chemische Nozizeption auftreten und sich bei Bewegungen verstärken, die auf das betroffene Segment einwirken“
(Crock 1986)

[Spine J.](#) 2005 Jul-Aug;5(4):370-80.

Centralization as a predictor of provocation discography results in chronic low back pain, and the influence of disability and distress on diagnostic power.

[Laslett M](#), [Obergr B](#), [Aprill CN](#), [McDonald B](#).

[Spine](#)1997 May 15;22(10):1115-22.

A prospective study of centralization of lumbar and referred pain. A predictor of symptomatic discs and anular competence.

[Donelson R](#), [Aprill C](#), [Medcalf R](#), [Grant W](#).

Einführung

ISG

Facetten

Discus

Piriformis

Take Home

Discogener Schmerz



[Spine](#) 2014 Jul 15;39(16):1314-24.

Nonoperative management of discogenic back pain: a systematic review.

[Lu Y](#), [Guzman JZ](#), [Purmessur D](#), [Iatridis JC](#), [Hecht AC](#), [Qureshi SA](#), [Cho SK](#)

Einführung

ISG

Facetten

Discus

Piriformis

Take Home

Discogener Schmerz



[Spine](#) 2014 Jul 15;39(16):1314-24.

Nonoperative management of discogenic back pain: a systematic review.

[Lu Y](#), [Guzman JZ](#), [Purmessur D](#), [Iatridis JC](#), [Hecht AC](#), [Qureshi SA](#), [Cho SK](#)

Einführung

ISG

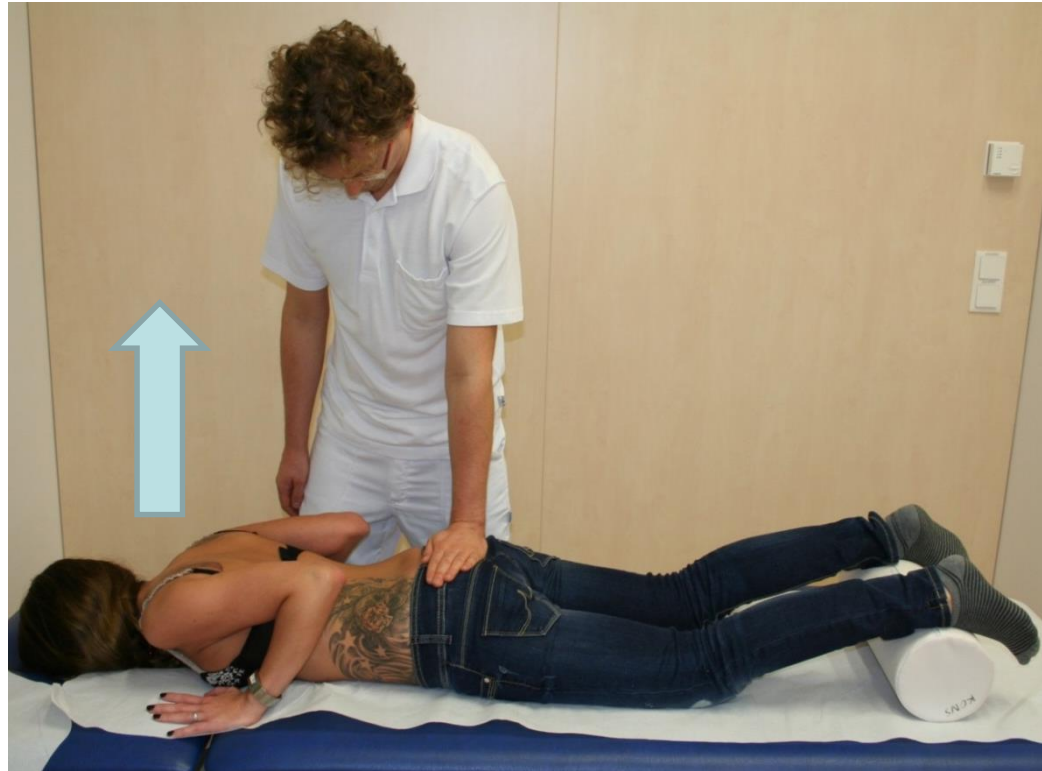Facetten

Discus

Piriformis

Take Home

Discogener Schmerz



[Spine](#) 2000 Feb 15;25(4):431-7; discussion 438.

Effects of backward bending on lumbar intervertebral discs. Relevance to physical therapy treatments for low back pain.

[Adams MA](#), [May S](#), [Freeman BJ](#), [Morrison HP](#), [Dolan P](#).

Einführung

ISG

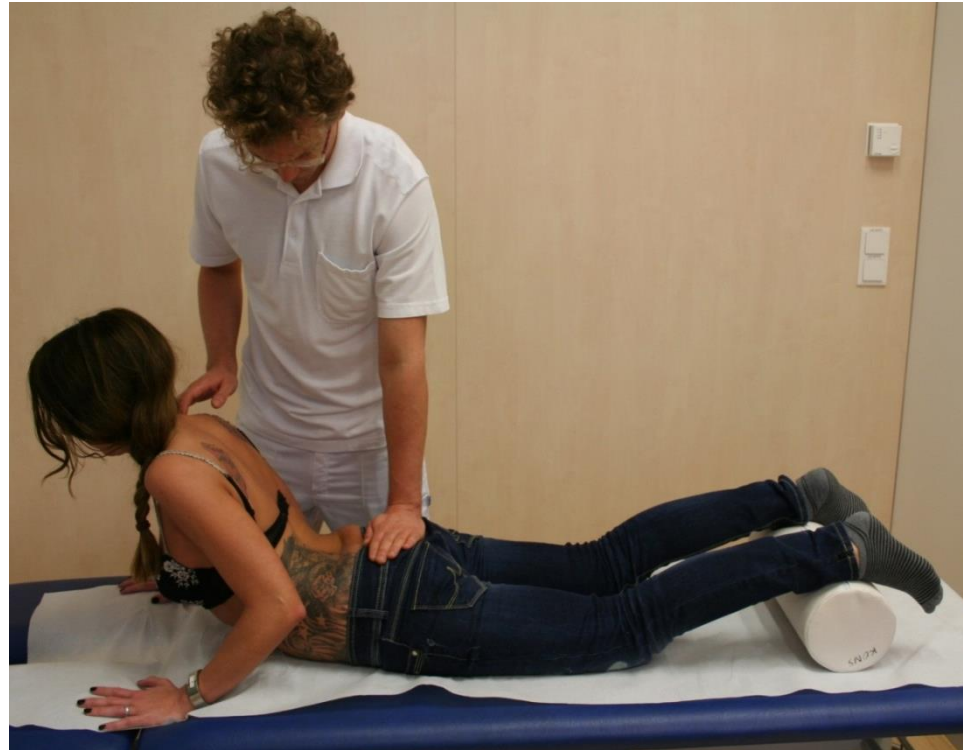Facetten

Discus

Piriformis

Take Home

Discogener Schmerz



[Spine](#) 2000 Feb 15;25(4):431-7; discussion 438.

Effects of backward bending on lumbar intervertebral discs. Relevance to physical therapy treatments for low back pain.

[Adams MA](#), [May S](#), [Freeman BJ](#), [Morrison HP](#), [Dolan P](#).

Einführung

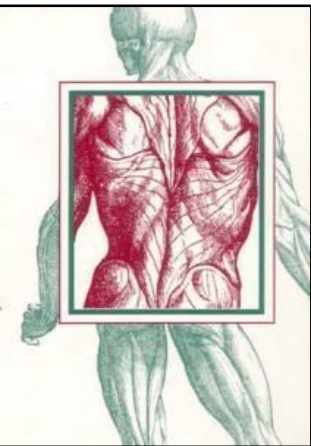
ISG

Facetten

Discus

Piriformis

Take Home



Diskogener Schmerz

Therapie

Einführung

ISG

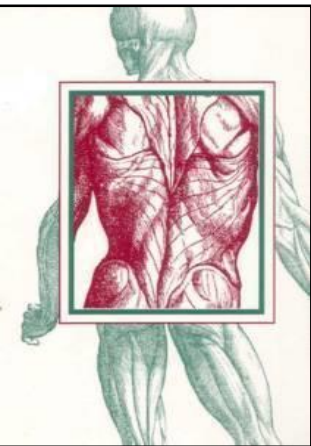
Facetten

Discus

Piriformis

Take Home

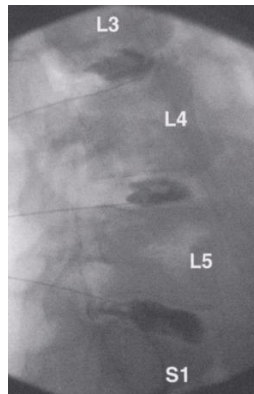
Spezifischer Kreuzschmerzen



Diskogener Schmerz

Therapie

**Infiltration/
Discographie?**



Einführung

ISG

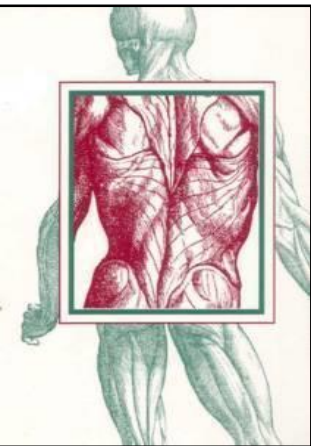
Facetten

Discus

Piriformis

Take Home

Spezifischer Kreuzschmerzen

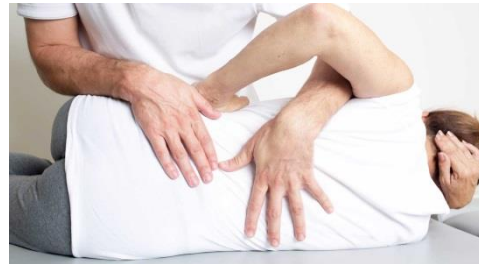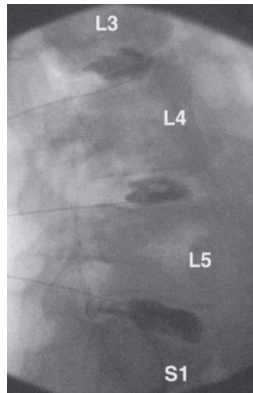


Diskogener Schmerz

Therapie

Infiltration/
Discographie?

Manuelle Medizin



Einführung

ISG

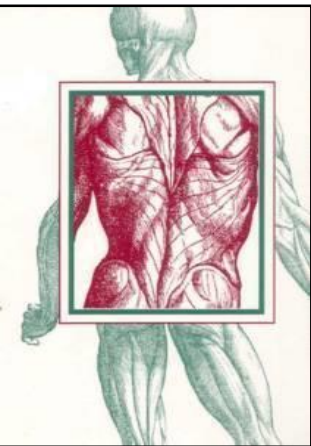
Facetten

Discus

Piriformis

Take Home

Spezifischer Kreuzschmerzen



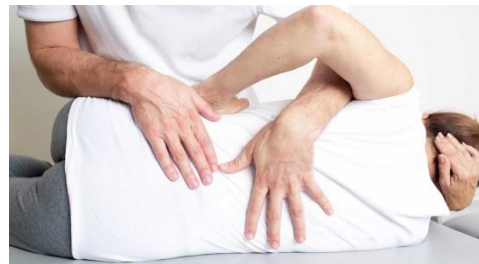
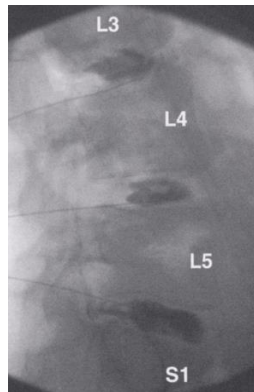
Diskogener Schmerz

Therapie

Infiltration/
Discographie?

Manuelle Medizin

Physiotherapie



Einführung
ISG

Facetten

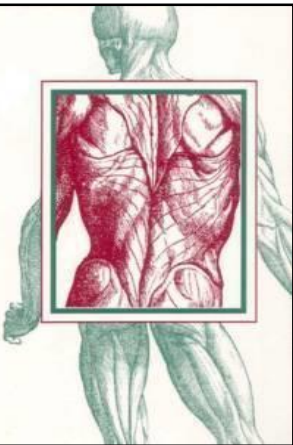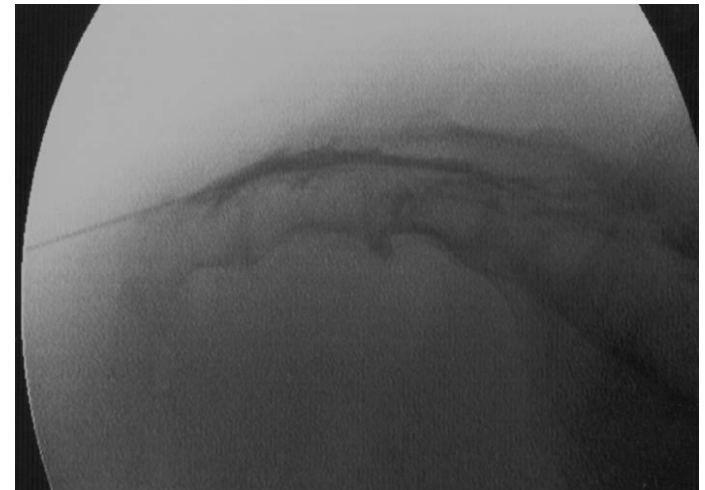
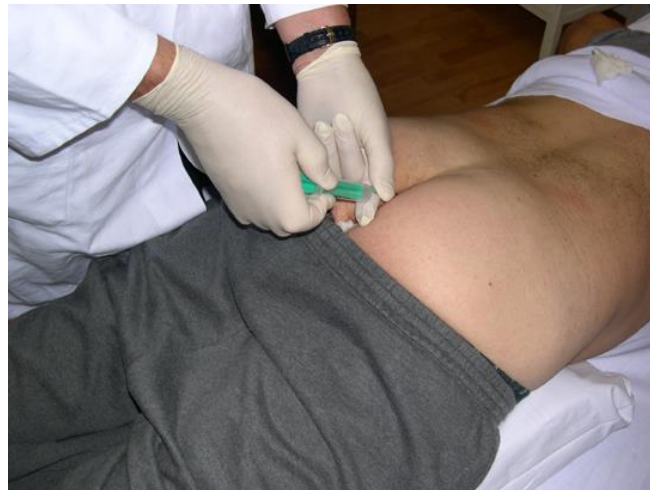Discus

Piriformis

Take Home

Discogener Schmerz

sakral epidurale Infiltration



Einführung

ISG

Facetten

Discus

Piriformis

Take Home

[Manchikanti L](#)¹, [Staats PS](#)², [Nampiarampil DE](#)³, [Hirsch JA](#)⁴.

What is the Role of Epidural Injections in the Treatment of Lumbar Discogenic Pain: A Systematic Review of Comparative Analysis with Fusion. Korean J Pain 2015 Apr;28(2):75-87.

Discogener Schmerz

Biacuplastie

Bipolare, gekühlte Radiofrequenztherapie für Bandscheiben zur Koagulation und Druckentlastung des Diskus.

Einführung

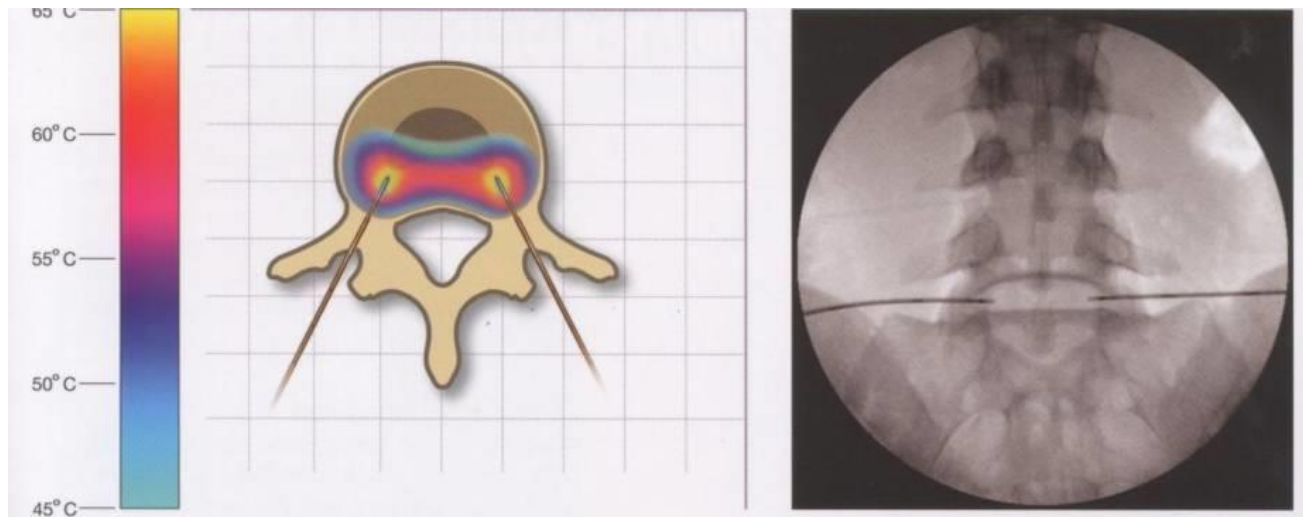
ISG

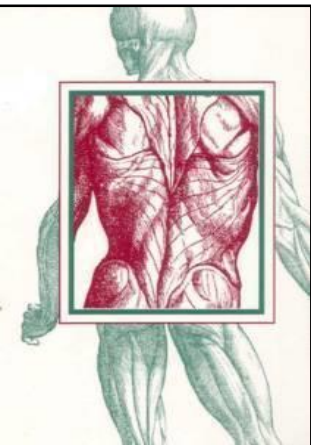
Facetten

Discus

Piriformis

Take Home





Discogener Schmerz

Biacuplastie

Bipolare, gekühlte Radiofrequenztherapie für Bandscheiben zur Koagulation und Druckentlastung des Diskus.

Einführung

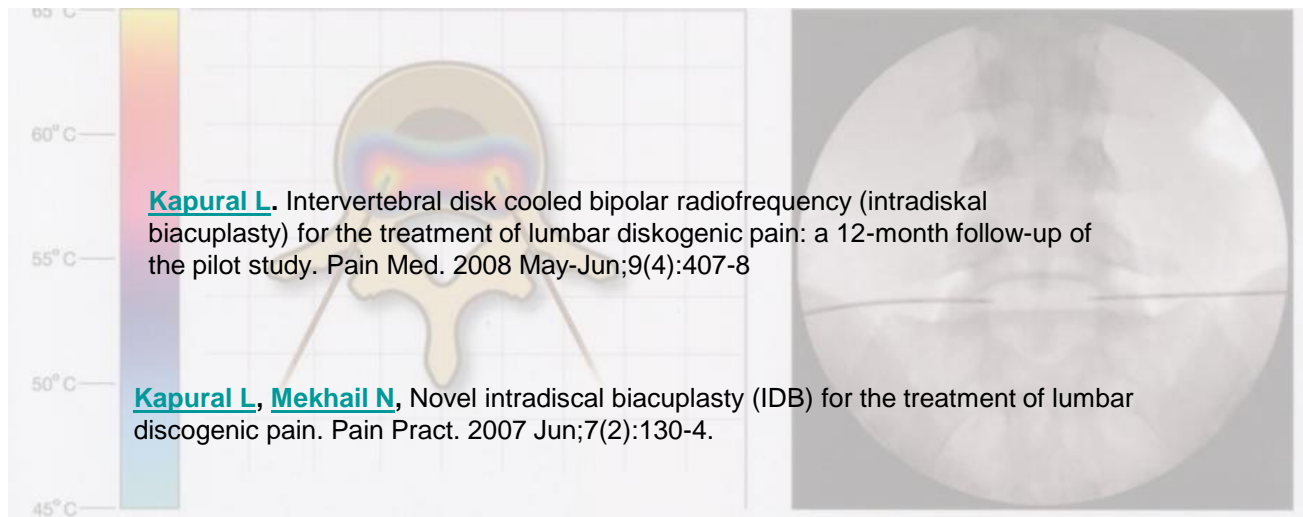
ISG

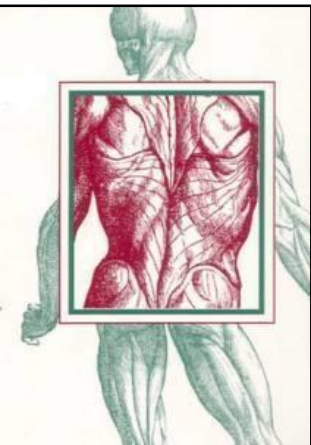
Facetten

Discus

Piriformis

Take Home

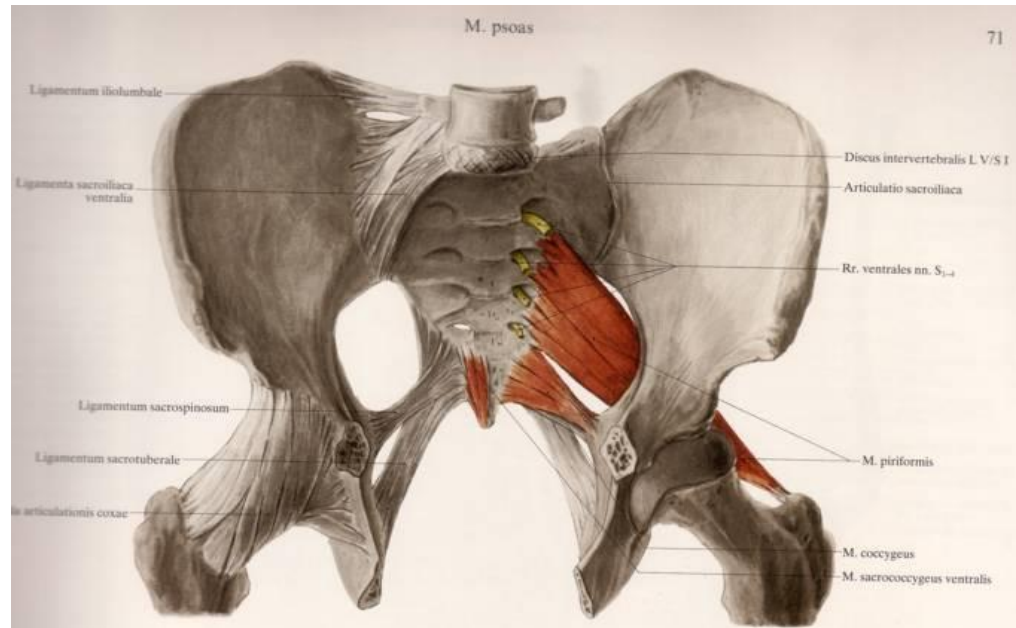




M. Piriformis

Ursprung: Innenfläche des Os Sacrum (Facies pelvina und die Foramina sacralia anteriora I-IV)

Ansatz: Spitze des Trochanter major



Einführung

ISG

Facetten

Discus

Piriformis

Take Home

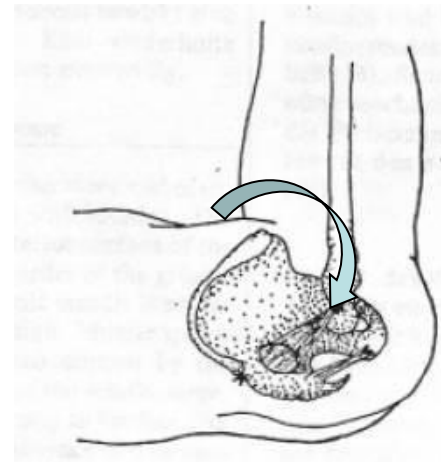
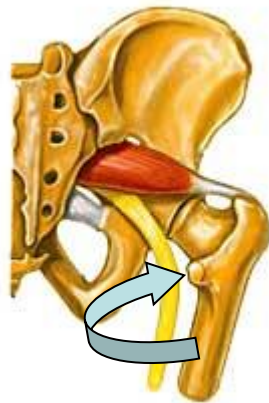
Funktion des M. Piriformis:

Außenrotation → bei Hüftstreckung

Abduktion

Innenrotation

ab 60° Hüftbeugung



Einführung

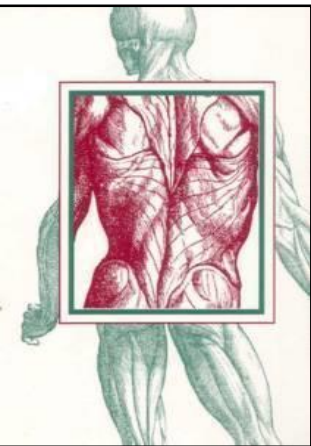
ISG

Facetten

Discus

Piriformis

Take Home



Pathogenese :

Epineurale Reizung des N. ischiadicus durch:

- Mechanische Irritation (Myogelose, Spasmus)
- Entzündungsreiz (interstitielle Myofibrositis, Neuritis)

[Solheim LF](#), [Siewers P](#), [Paus B](#). The piriformis muscle syndrome. Sciatic nerve entrapment treated with section of the piriformis muscle. Acta Orthop Scand. 1981 Feb;52(1):73-5.

[Lundborg G](#). Structure and function of the intraneural microvessels as related to trauma, edema formation, and nerve function. J Bone Joint Surg Am. 1975 Oct;57(7):938-48.

[Awad EA](#). Interstitial myofibrositis: hypothesis of the mechanism, Arch Phys Med Rehabil. 1973 Oct;54(10):449-53.

Einführung

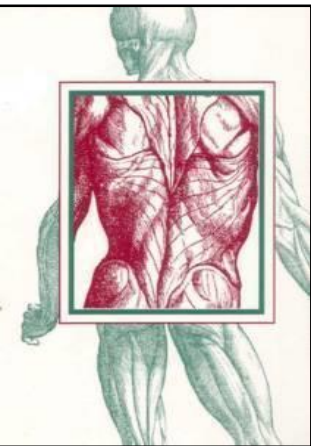
ISG

Facetten

Discus

Piriformis

Take Home



Prävalenz:

6-8 % aller Kreuzschmerzen

Frauen 6x häufiger betroffen als Männer

[Filler AG](#), [Haynes J](#), [Jordan SE](#), [Prager J](#), [Villablanca JP](#), [Farahani K](#), [McBride DQ](#), [Tsuruda JS](#), [Morisoli B](#), [Batzdorf U](#), [Johnson JP](#). Sciatica of nondisc origin and piriformis syndrome: diagnosis by magnetic resonance neurography and interventional magnetic resonance imaging with outcome study of resulting treatment. J Neurosurg Spine. 2005 Feb;2(2):99-115.

[Hallin RP](#). Sciatic pain and the piriformis muscle, Postgrad Med. 1983 Aug;74(2):69-72.

[Pace JB](#), [Nagle D](#), Piriformis syndrome, West J Med. 1976 Jun; 124(6):435-9.

Einführung

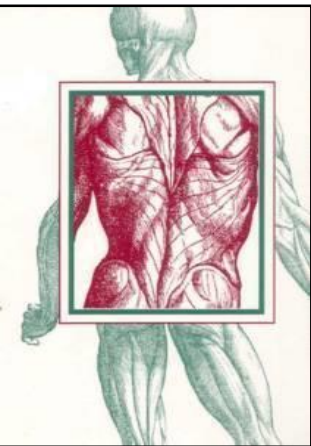
ISG

Facetten

Discus

Piriformis

Take Home



Anamnese :

- häufig Trauma
- Schmerzverstärkung durch langes Sitzen
- Schmerzausstrahlung gluteal, inguinal und ischialgiform möglich

Simons DG, Travell JG. Myofascial origins of low back pain. 3. Pelvic and lower extremity muscles, Postgrad Med. 1983 Feb;73(2):99-105, 108.

Pećina M. Contribution to the etiological explanation of the piriformis syndrome , Acta Anat (Basel). 1979;105(2):181-7.

Einführung

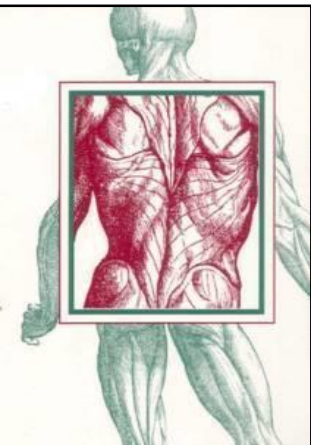
ISG

Facetten

Discus

Piriformis

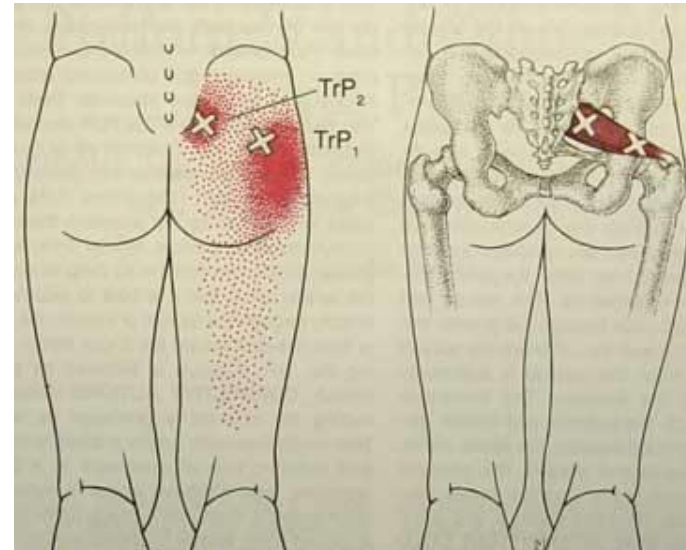
Take Home



Klinik :

M.Piriformis ist druckempfindlich

Trigger Punkte



[Pfeifer T, Fitz WF](#). The piriformis syndrome, Z Orthop Ihre Grenzgeb. 1989 Nov-Dec;127(6):691-4.

[Travell J.G., Daitz, B.](#) Myofascial Pain Syndromes: The Travell Trigger-Point Tapes. Myofascial Pain Syndromes of the Low Back and Hip. Baltimore, Maryland; Williams & Wilkins Electronic Media.

Einführung

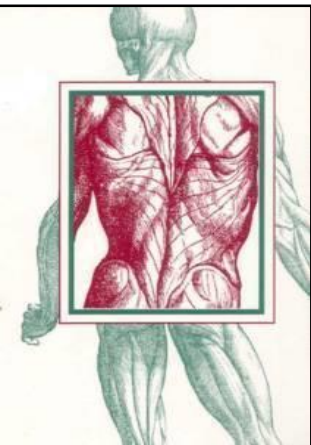
ISG

Facetten

Discus

Piriformis

Take Home



Klinik :

FAIR Test: Flexion, Adduktion, Innenrotation

Fishman LM, Dombi GW, Michaelsen C, Ringel S, Rozbruch J, Rosner B, Weber C.
Piriformis syndrome: diagnosis, treatment, and outcome--a 10-year study. Arch Phys Med Rehabil. 2002 Mar;83(3):295-301

Einführung

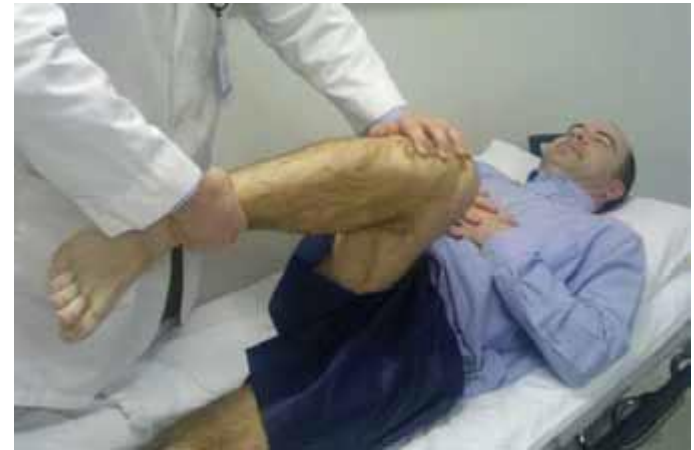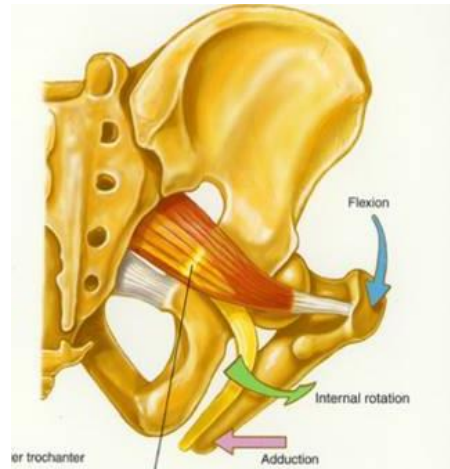
ISG

Facetten

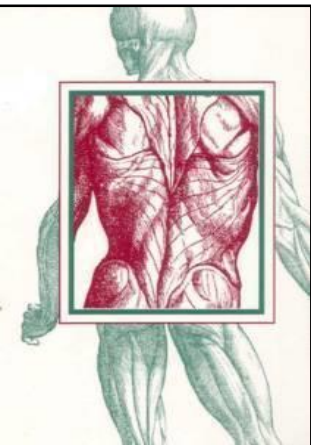
Discus

Piriformis

Take Home



- 918 Patienten (Follow up 733)
- 97% der FAIR-Test pos. Patienten profitierten von der Therapie des M. Piriformis



Klinik :


Rektale Untersuchung ?

Hinks AH, Letter: Further aid for piriformis muscle syndrome. J Am Osteopath Assoc. 1974 Oct;74(2):93

Pace JB, Nagle D, Piriformis syndrome, West J Med. 1976 Jun; 124(6):435-9.

Wyant GM. Chronic pain syndromes and their treatment. III. The piriformis syndrome. Can Anaesth Soc J. 1979 Jul;26(4):305-8.

Steiner C, Staubs C, Ganon M, Buhlinger C, Piriformis syndrome: pathogenesis, diagnosis, and treatment. J Am Osteopath Assoc. 1987 Apr;87(4):318-23.



Einführung

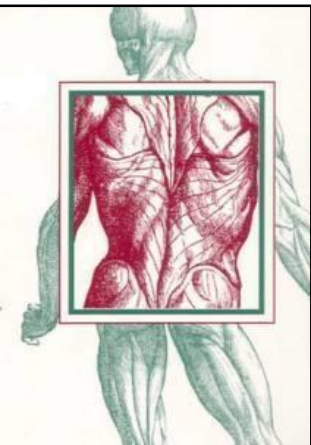
ISG

Facetten

Discus

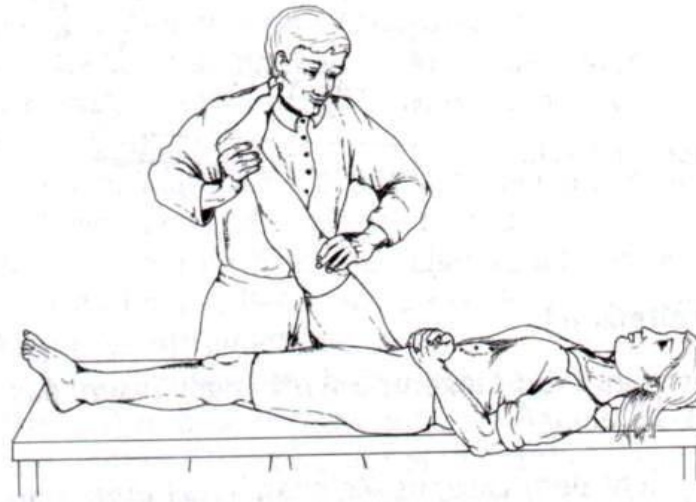
Piriformis

Take Home



Klinik :

Lasegue-Test kann positiv sein !



[Breig A, Troup J](#), Biomechanical considerations in the straight leg raising test. Cadaveric and clinical studies of medial hip rotation. 1979 Spine 4 (3): 242-250

[Freiburg AH, Vinke TA](#): "Sciatica and the sacroiliac join." J Bone Joint Surg 16:126, 1934.

Einführung

ISG

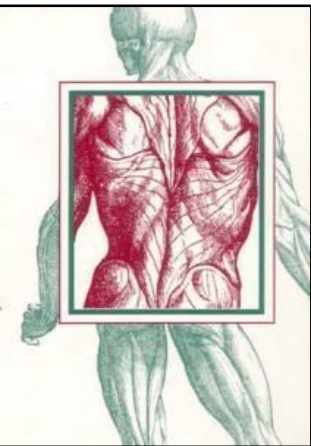
Facetten

Discus

Piriformis

Take Home

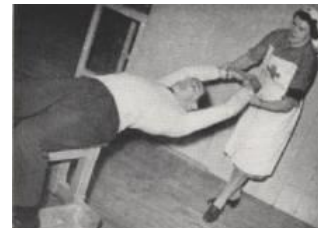Spezifischer Kreuzschmerzen



Therapie: 3 Säulen



Infiltration



Physiotherapie



**Verhaltens-
maßnahmen**



Einführung

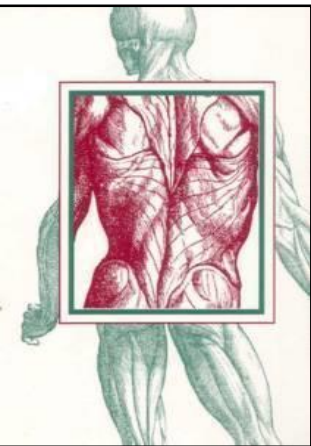
ISG

Facetten

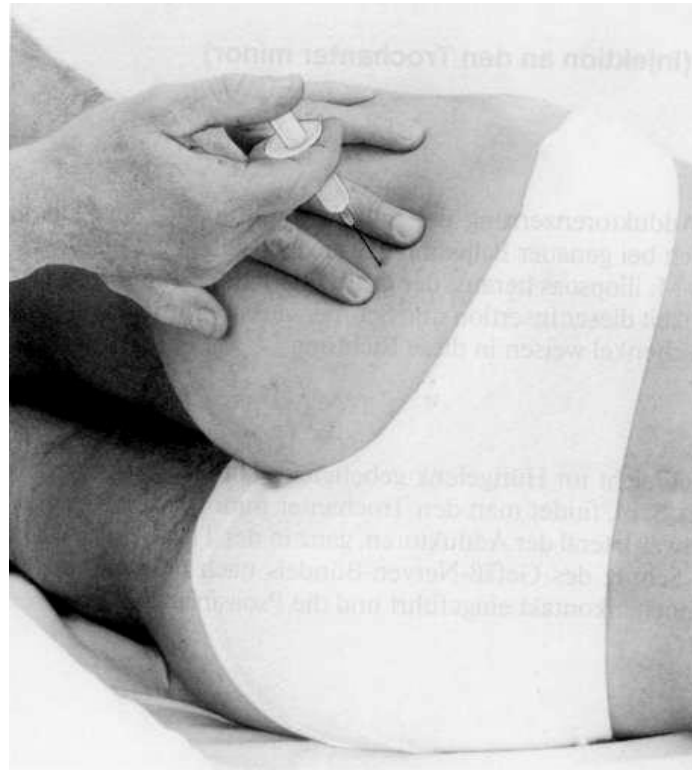Discus

Piriformis

Take Home



Infiltrationstherapie



Einführung

ISG

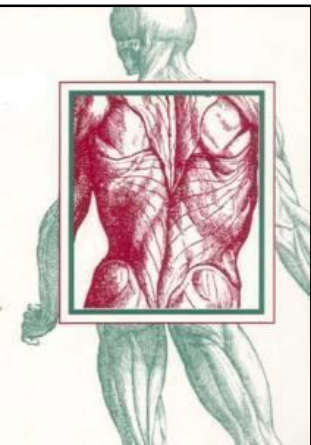
Facetten

Discus

Piriformis

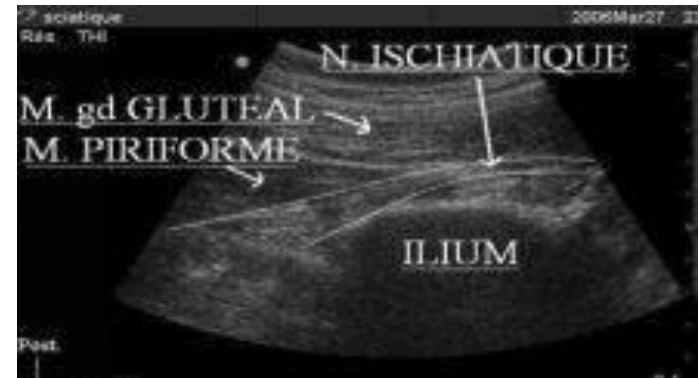
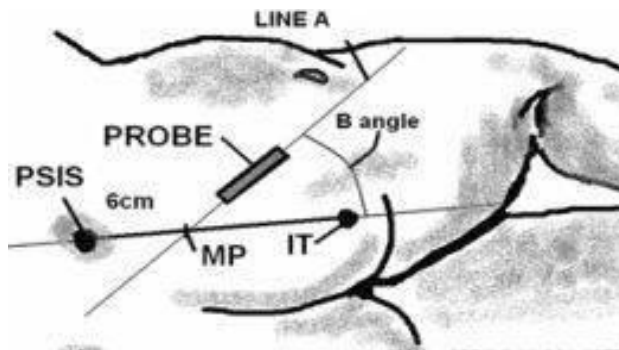
Take Home

Benzon HT, Katz JA, Benzon HA, Iqbal MS, Piriformis syndrome: anatomic considerations, a new injection technique, and a review of the literature. *Anesthesiology*. 2003 Jun;98(6):1442-8



Infiltrationstherapie

sonographisch unterstützt



Einführung

ISG

Facetten

Discus

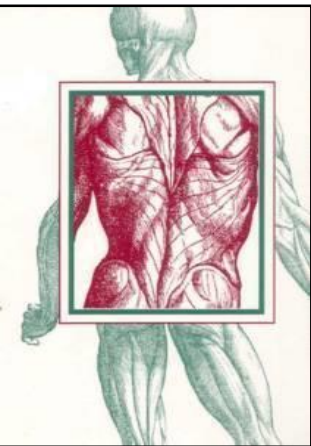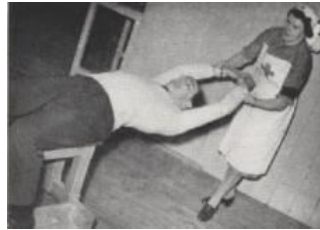
Piriformis

Take Home

[Finnoff JT](#), [Hurdle MF](#), [Smith J](#). Accuracy of ultrasound-guided versus fluoroscopically guided contrast-controlled piriformis injections: a cadaveric study. *J Ultrasound Med.* 2008 Aug;27(8):1157-63

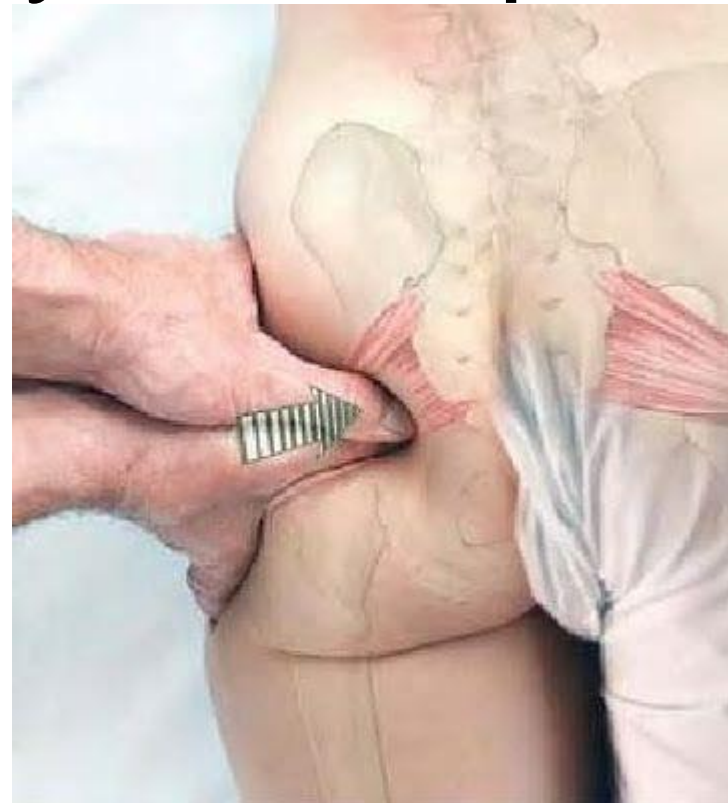[Reus M](#), [de Dios Berná J](#), [Vázquez V](#), [Redondo MV](#), [Alonso J](#). Piriformis syndrome: a simple technique for US-guided infiltration of the perisciatic nerve. Preliminary results. *Eur Radiol.* 2008 Mar;18(3):616-20. Epub 2007 Oct 31

[Smith J](#), [Hurdle MF](#), [Locketz AJ](#), [Wisniewski SJ](#). Ultrasound-guided piriformis injection: technique description and verification. *Arch Phys Med Rehabil.* 2006 Dec;87(12):1664-7



Physiotherapie

- TP



Einführung

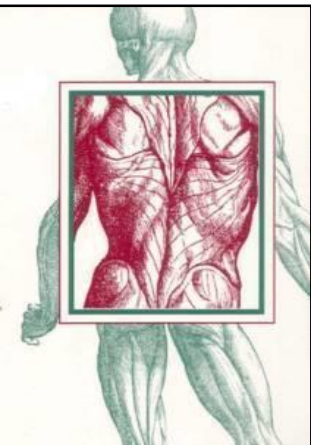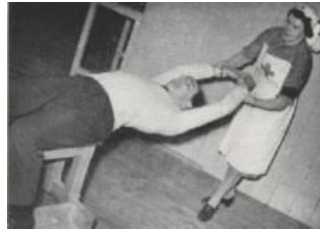
ISG

Facetten

Discus

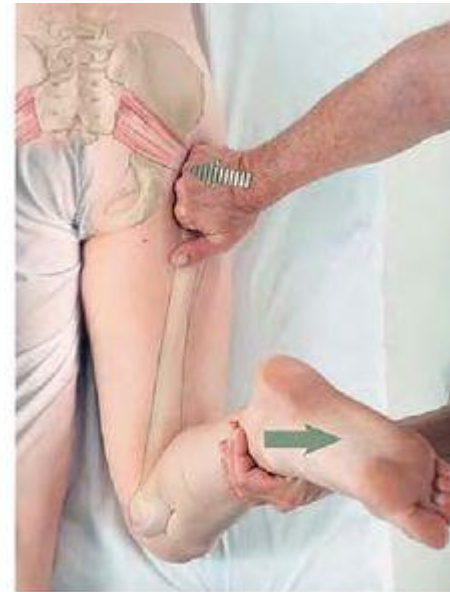Piriformis

Take Home



Physiotherapie

- TP
- Querfriktion



Einführung

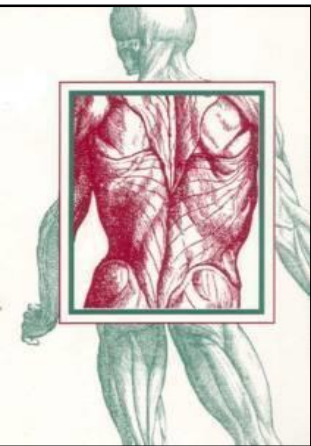
ISG

Facetten

Discus

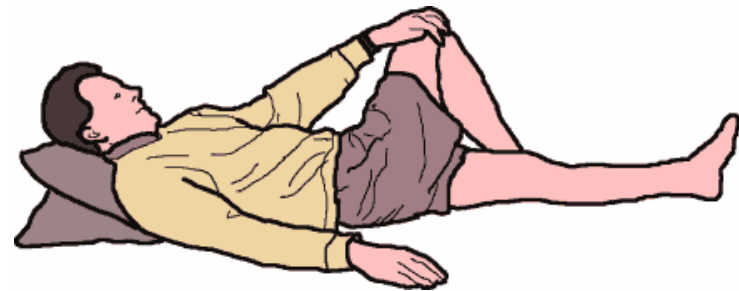Piriformis

Take Home



Physiotherapie

- TP
- Querfriktion
- Dehnung



Einführung

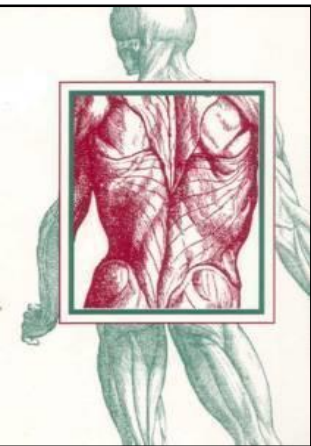
ISG

Facetten

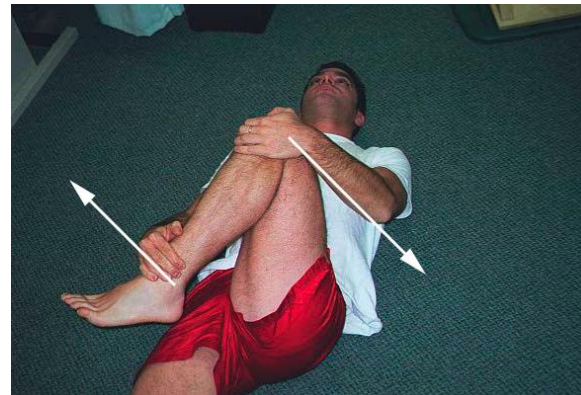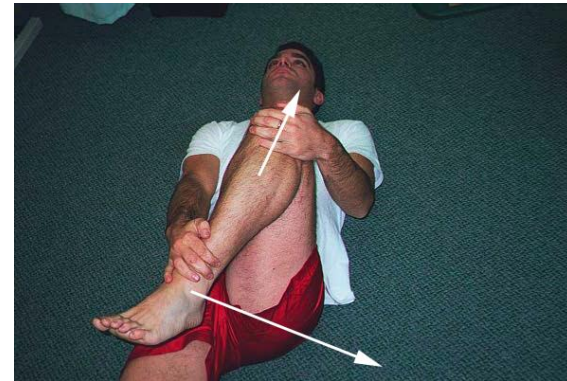Discus

Piriformis

Take Home



Physiotherapie



- TP
- Querfriktion
- Dehnung
- PIR

Einführung

ISG

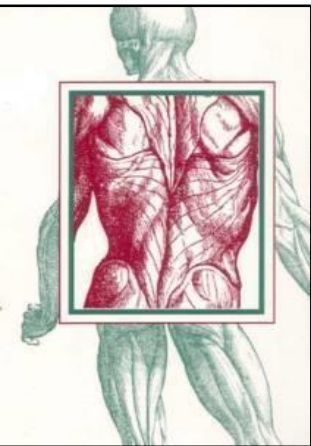
Facetten

Discus

Piriformis

Take Home

Spezifischer Kreuzschmerzen



- CAVE: Tennis, Fußball, Volleyball, Laufen
- Geldbörse in der Gesäßtasche
- Längeres Sitzen vermeiden
- Beim Schlafen in Seitenlage: Polster zwischen den Beinen

Einführung

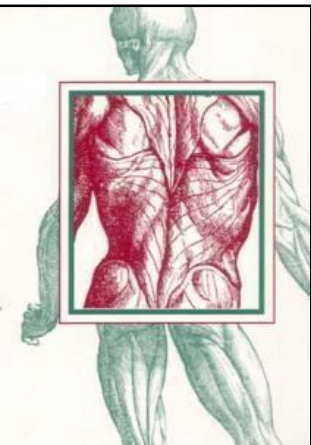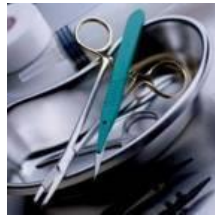
ISG

Facetten

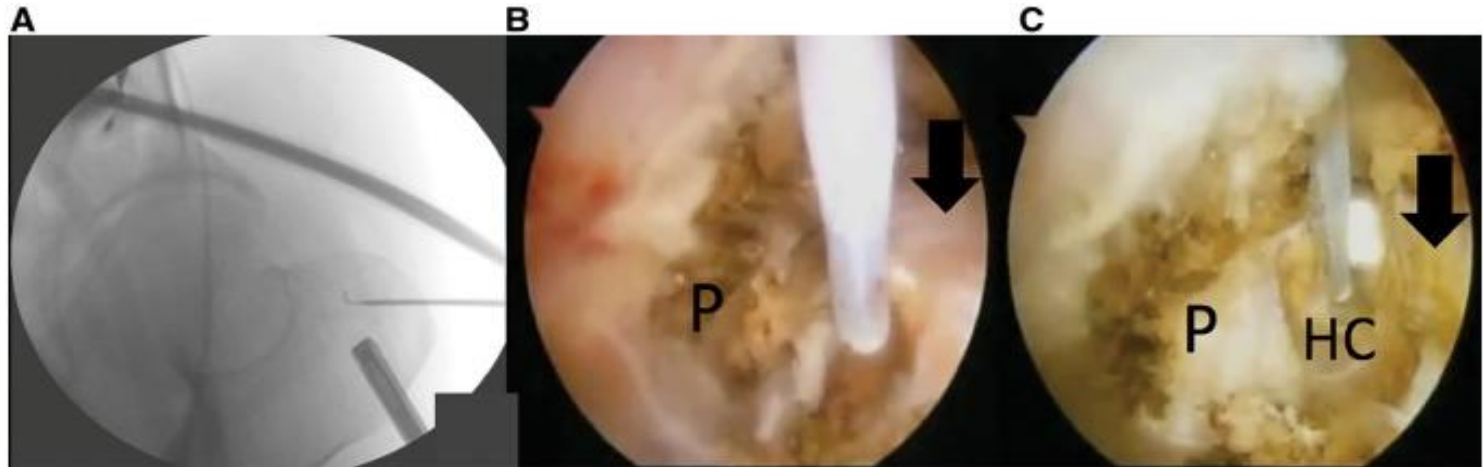
Discus

Piriformis

Take Home



Operation



Einführung

ISG

Facetten

Discus

Piriformis

Take Home

[Kay J](#), [de Sa D](#), [Morrison L](#), [Fejtek E](#), [Simunovic N](#), [Martin HD](#), [Ayeni OR](#)

Surgical Management of Deep Gluteal Syndrome Causing Sciatic Nerve Entrapment: A Systematic Review. [Arthroscopy](#). 2017

[Ilizaliturri VM Jr](#), [Arriaga R](#), [Villalobos FE](#), [Suarez-Ahedo C](#)

Endoscopic release of the piriformis tendon and sciatic nerve exploration. [J Hip Preserv Surg](#). 2018 Aug.

Take Home Message



Einführung

ISG

Facetten

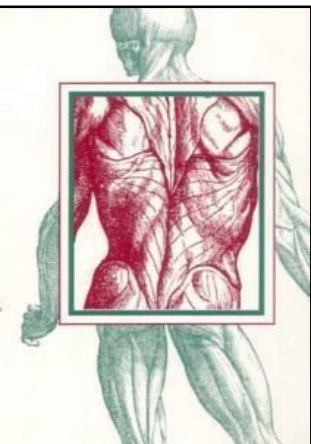
Discus

Piriformis

Take Home

Spezifischer Kreuzschmerzen

medikamentöse Empfehlung spezifischer Kreuzschmerz



Entität	NSAR	Paracetamol	Metamizol	Opioide	Anti-konvulsiva	Anti-depressiva	Muskel-relaxanzien
Facettensyndrom	+	+/-	+	-	-	-	+/-
Discogenes Lumbalsyndrom	+	-	+	-	-	-	-
Axiale Spondylarthropathie	+	-	+	-	-	-	-
Morbus Bastrup	+	-	+	-	-	-	-
Spinalkanalstenose	+	-	+	+	+	-	-
Spondylolisthese	+	-	+	-	-	-	-
Discusprolaps mit Radikulopathie	+	+/-	+	+	+	+/-	-
Osteoporotische Wirbelkörperfraktur	+	-	+	+	-	-	+/-
ISG Schmerzen	+	-	+	-	-	-	-
Myogelosen	+	+/-	+	-	-	-	+
Blockierung	+	-	+	-	-	-	+/-

© Peter Machacek

Einführung

ISG

Facetten

Discus

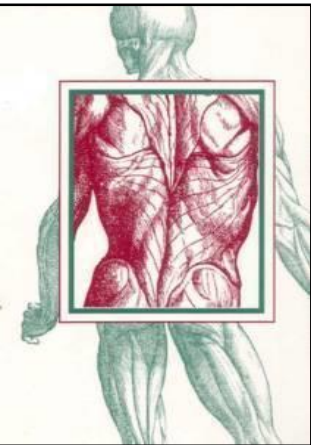
Piriformis

Take Home

Spezifischer Kreuzschmerzen

medikamentöse Empfehlung spezifischer Kreuzschmerz

Entität	NSAR	Paracetamol	Metamizol	Opioide	Anti-konvulsiva	Anti-depressiva	Muskel-relaxanzien
Facettensyndrom	+	+/-	+	-	-	-	+/-
Discogenes Lumbalsyndrom	+	-	+	-	-	-	-
Axiale Spondylarthropathie	+	-	+	-	-	-	-
Morbus Bastrup	+	-	+	-	-	-	-
Spinalkanalstenose	+	-	+	+	+	-	-
Spondylolisthese	+	-	+	-	-	-	-
Discusprolaps mit Radikulopathie	+	+/-	+	+	+	+/-	-
Osteoporotische Wirbelkörperfraktur	+	-	+	+	-	-	+/-
ISG Schmerzen	+	-	+	-	-	-	-
Myogelosen	+	+/-	+	-	-	-	+
Blockierung	+	-	+	-	-	-	+/-

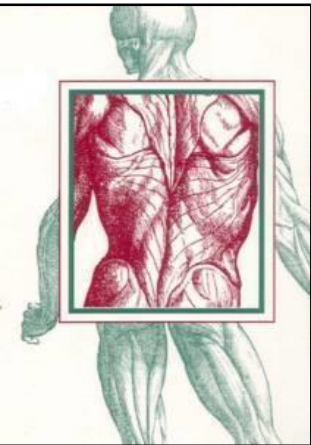


Einführung
ISG
Facetten
Discus
Piriformis
Take Home

Spezifischer Kreuzschmerzen

medikamentöse Empfehlung spezifischer Kreuzschmerz

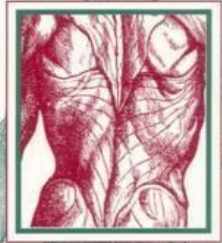
Entität	NSAR	Paracetamol	Metamizol	Opioide	Anti-konvulsiva	Anti-depressiva	Muskel-relaxanzien
Facettensyndrom	+	+/-	+	-	-	-	+/-
Discogenes Lumbalsyndrom	+	-	+	-	-	-	-
Axiale Spondylarthropathie	+	-	+	-	-	-	-
Morbus Bastrup	+	-	+	-	-	-	-
Spinalkanalstenose	+	-	+	+	+	-	-
Spondylolisthese	+	-	+	-	-	-	-
Discusprolaps mit Radikulopathie	+	+/-	+	+	+	+/-	-
Osteoporotische Wirbelkörperfraktur	+	-	+	+	-	-	+/-
ISG Schmerzen	+	-	+	-	-	-	-
Myogelosen	+	+/-	+	-	-	-	+
Blockierung	+	-	+	-	-	-	+/-



Einführung
ISG
Facetten
Discus
Piriformis
Take Home

Take Home Message

Lumbalgie



Einführung

ISG

Facetten

Discus

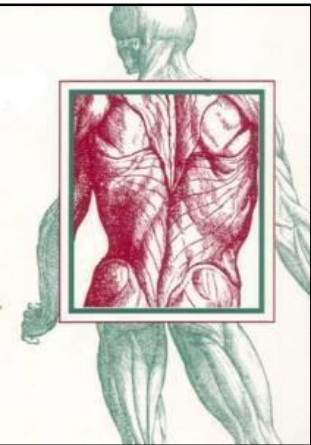

Piriformis

Take Home

Take Home Message

Lumbalgie

Radikulopathie



Einführung

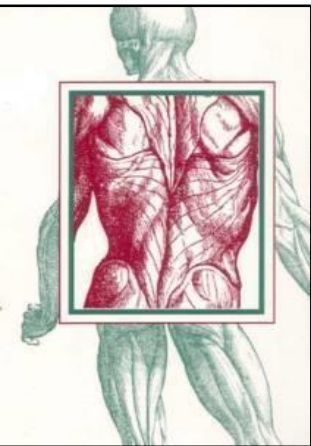
ISG

Facetten


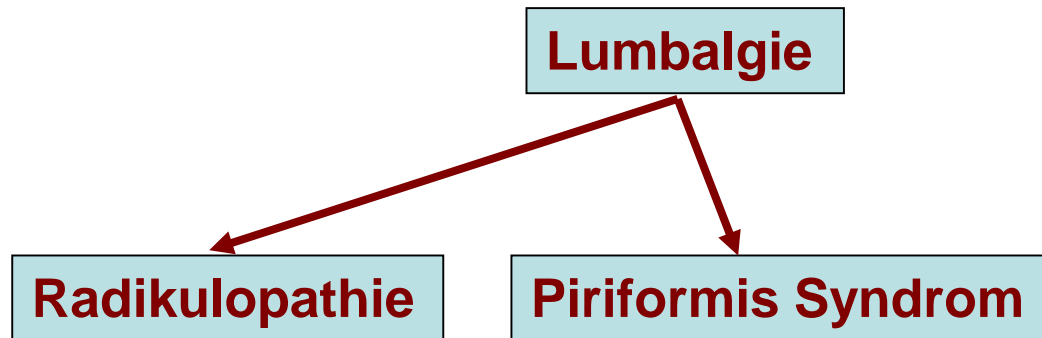
Discus

Piriformis

Take Home



Take Home Message



Einführung

ISG

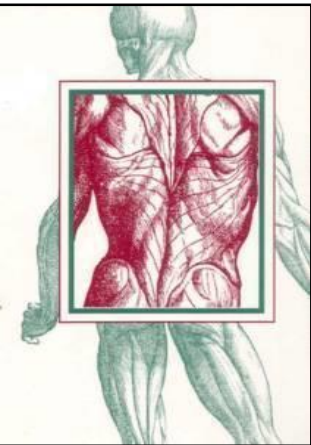
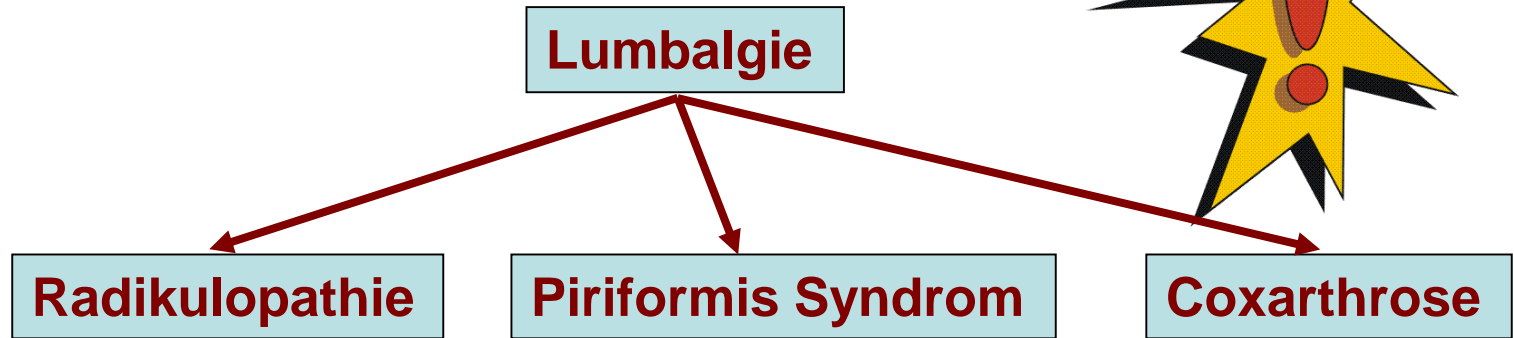
Facetten

Discus

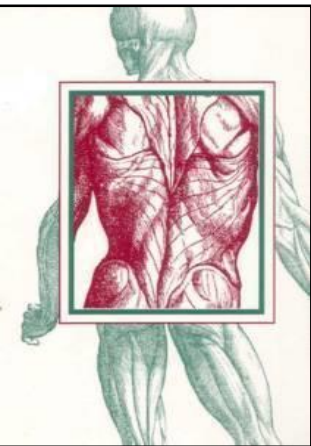
Piriformis

Take Home


Take Home Message



- Einführung
- ISG
- Facetten
- Discus
- Piriformis
- Take Home**



Take Home Message



Lumbalgie

Radikulopathie

Piriformis Syndrom

Coxarthrose

Einführung

ISG

Facetten

Discus

Piriformis

Take Home

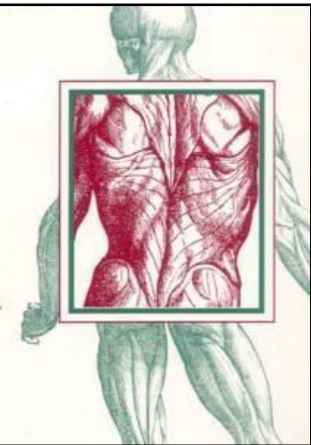
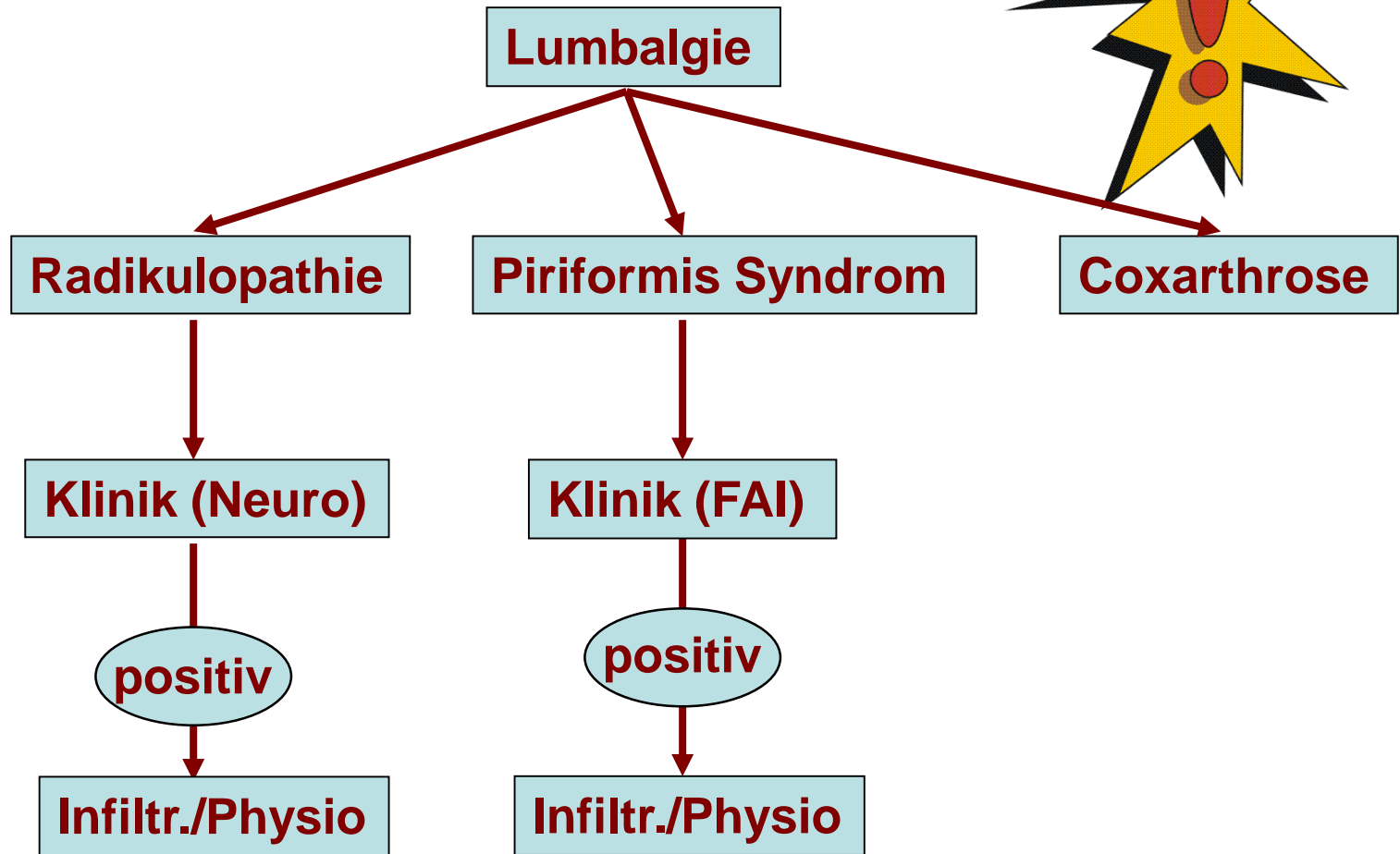

Klinik (Neuro)

positiv

Infiltr./Physio

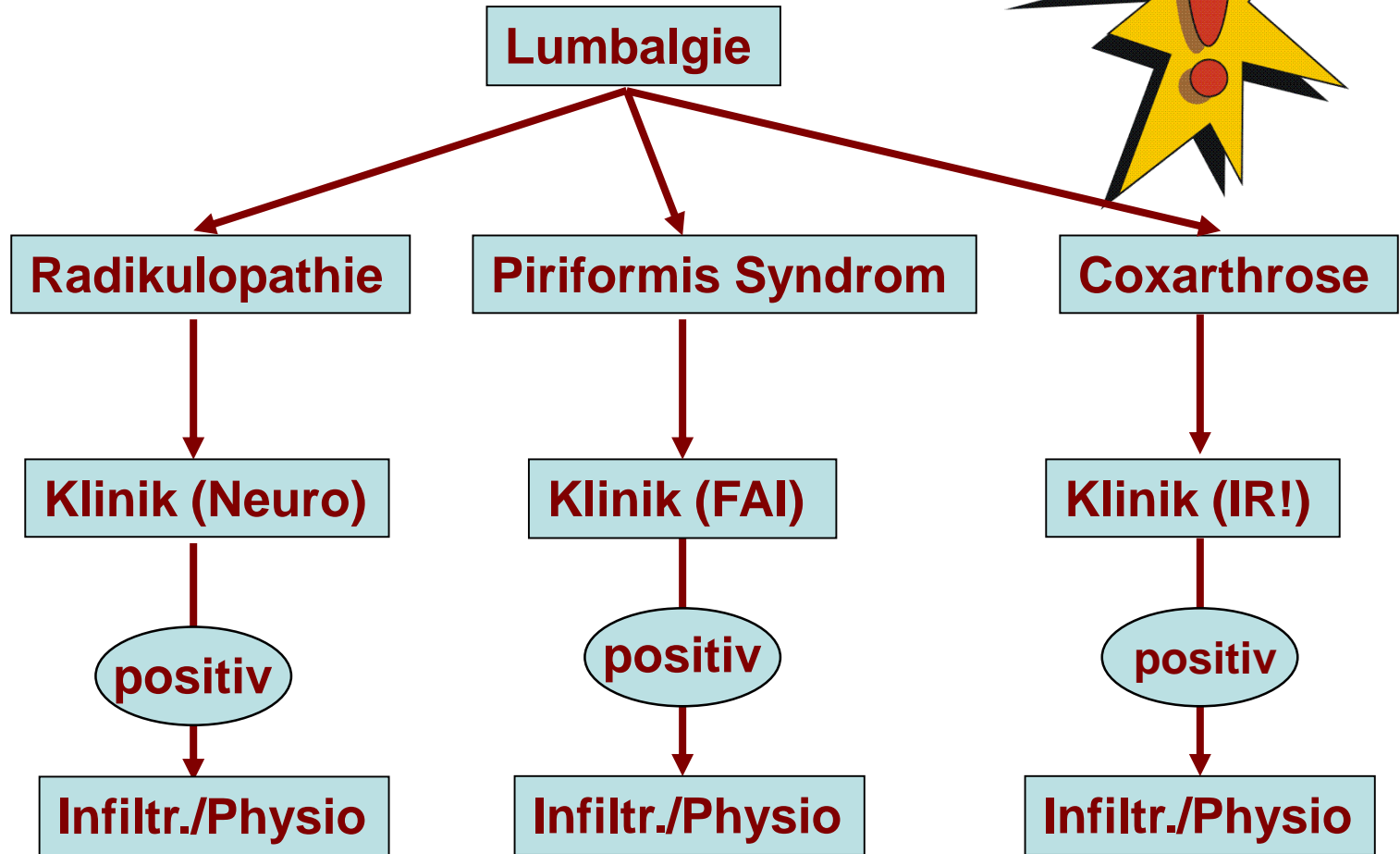

Spezifischer Kreuzschmerzen

Take Home Message



- Einführung
- ISG
- Facetten
- Discus
- Piriformis
- Take Home

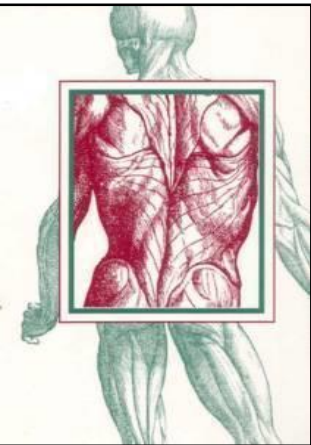
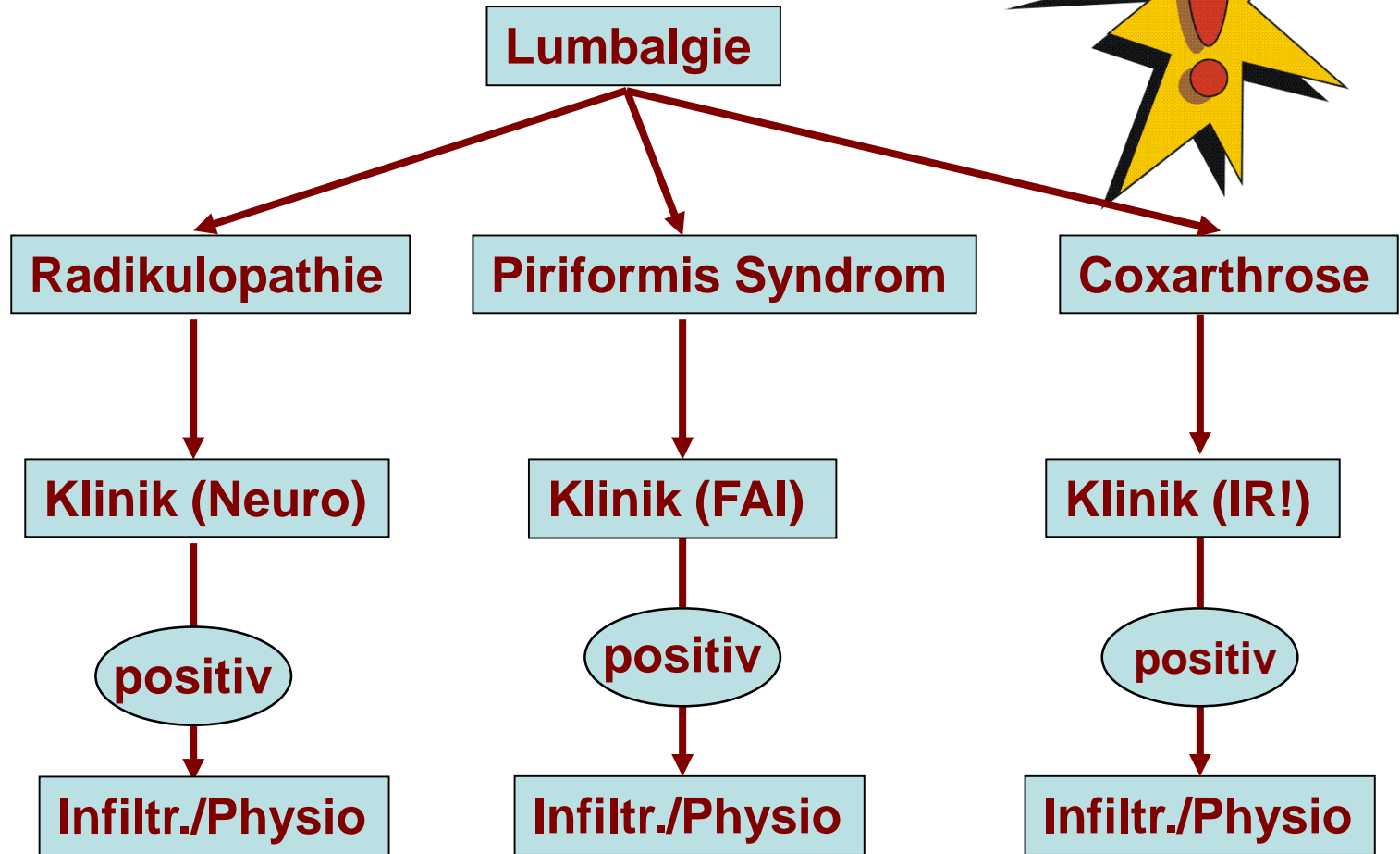

Take Home Message



Einführung
ISG
Facetten
Discus
Piriformis
Take Home

Spezifischer Kreuzschmerzen

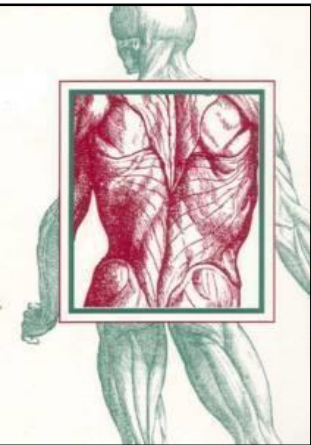

Take Home Message



- Einführung
- ISG
- Facetten
- Discus
- Piriformis
- Take Home

Take Home Message

Lumbalgie



Einführung

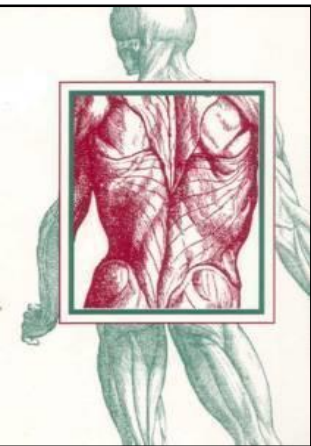
ISG

Facetten

Discus

Piriformis


Take Home



Take Home Message

Lumbalgie

ISG - Schmerz



Einführung

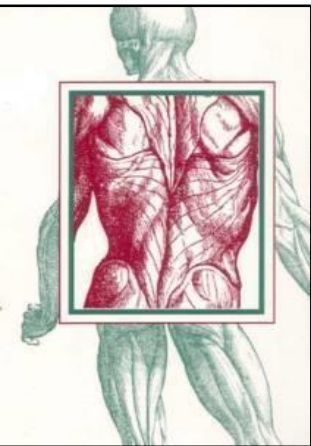
ISG

Facetten


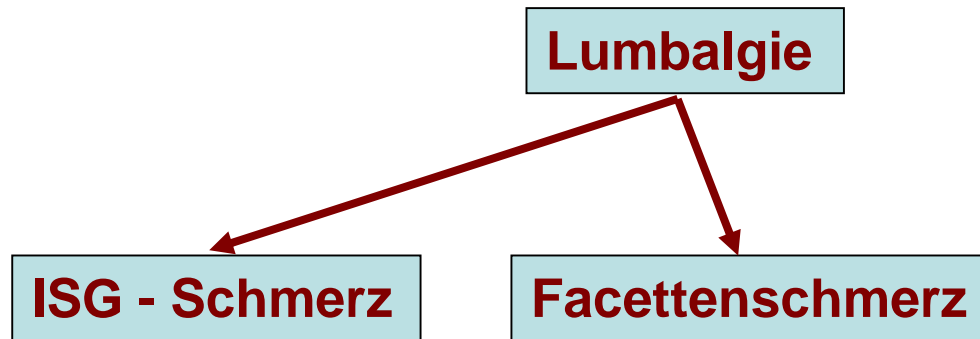
Discus

Piriformis

Take Home



Take Home Message



Einführung

ISG

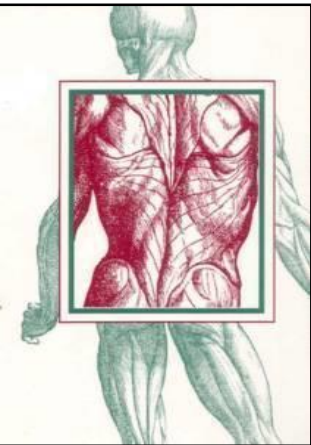
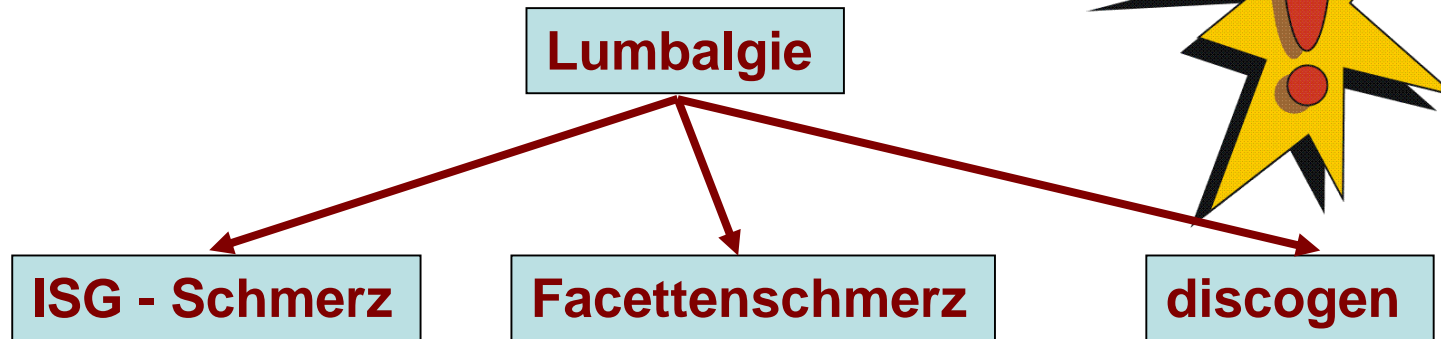
Facetten

Discus

Piriformis


Take Home

Take Home Message



- Einführung
- ISG
- Facetten
- Discus
- Piriformis
- Take Home**

Take Home Message



Lumbalgie

ISG - Schmerz

Facettenschmerz

discogen

Testung i.a.

Einführung

ISG


Facetten

Discus

Piriformis

Take Home

Take Home Message



Lumbalgie

ISG - Schmerz

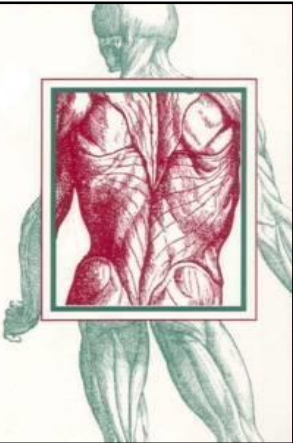
Facettenschmerz

discogen

Testung i.a.

positiv

RF Denervierung



Einführung

ISG

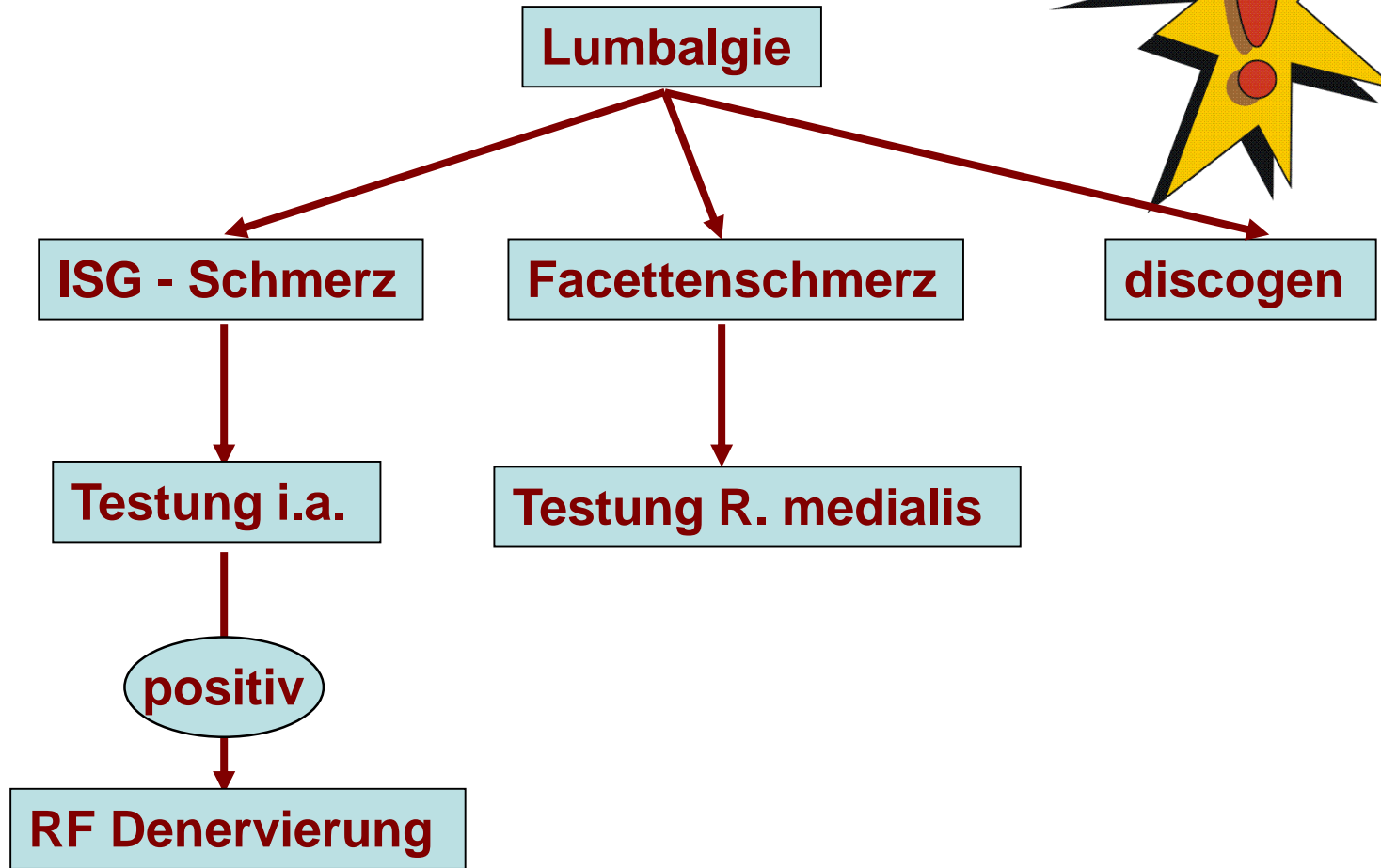
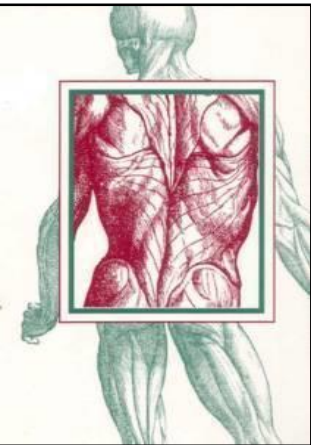

Facetten

Discus

Piriformis

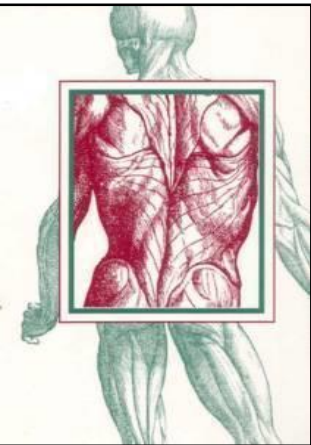
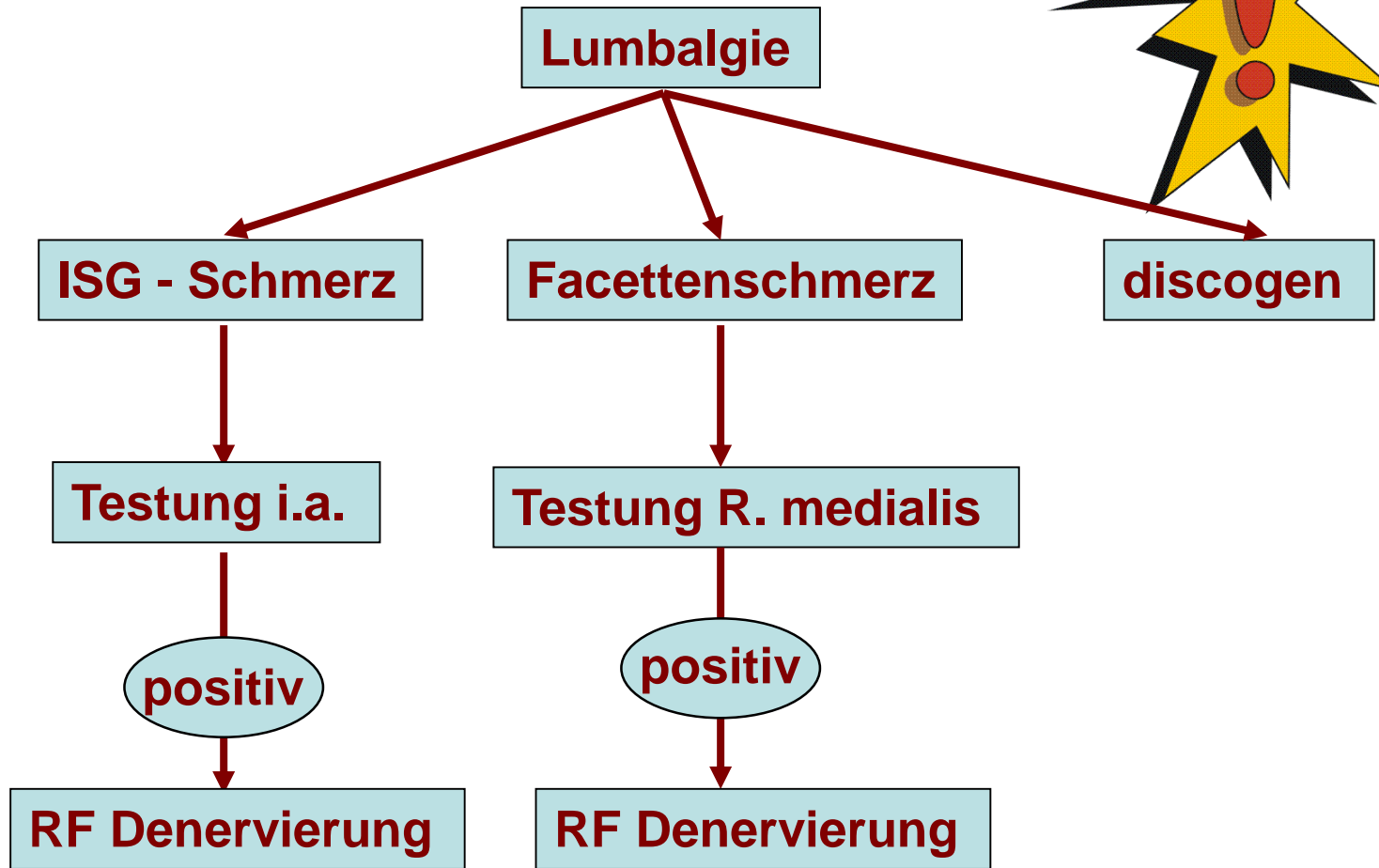

Take Home

Take Home Message



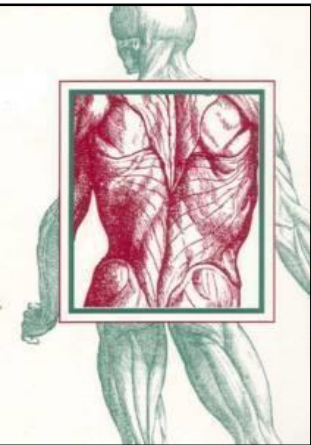
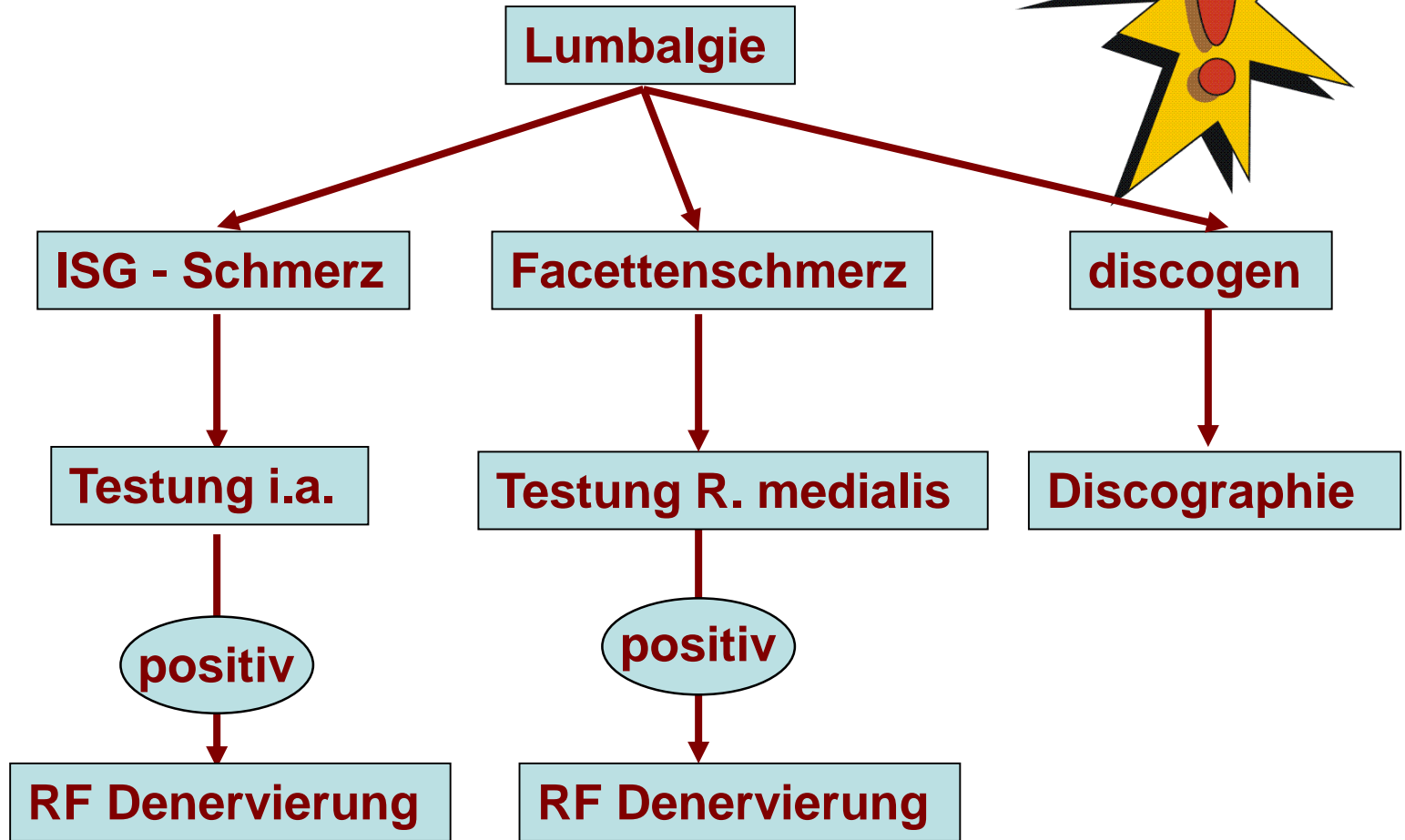

- Einführung
- ISG
- Facetten
- Discus
- Piriformis
- Take Home

Take Home Message



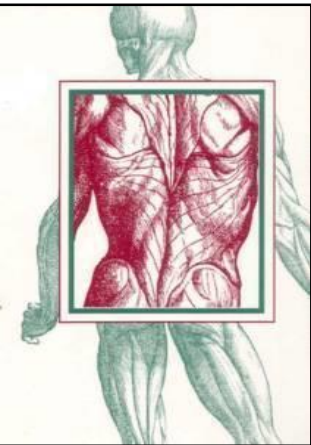
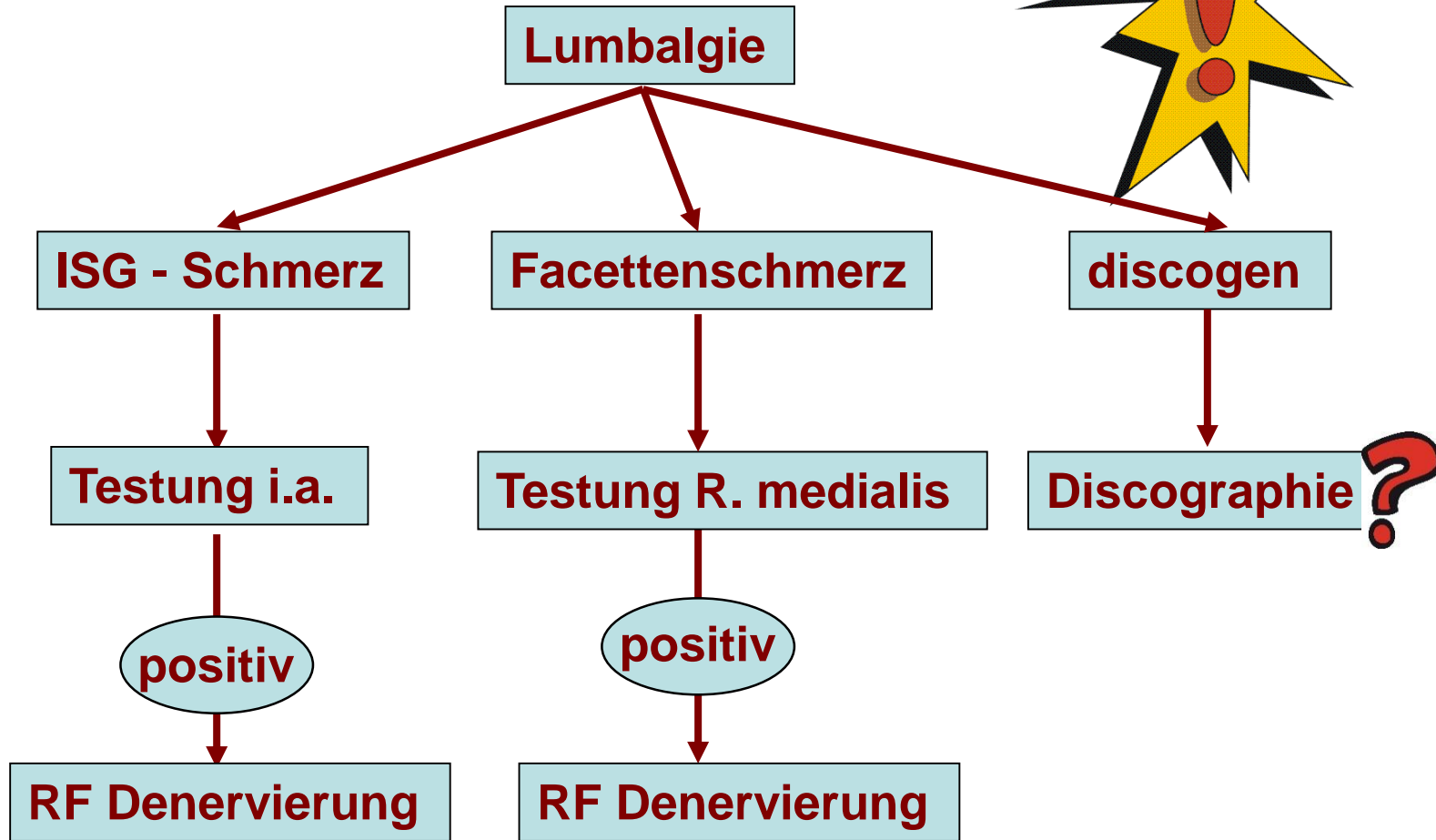

- Einführung
- ISG
- Facetten
- Discus
- Piriformis
- Take Home

Take Home Message



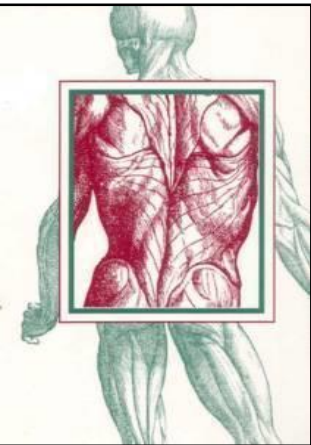
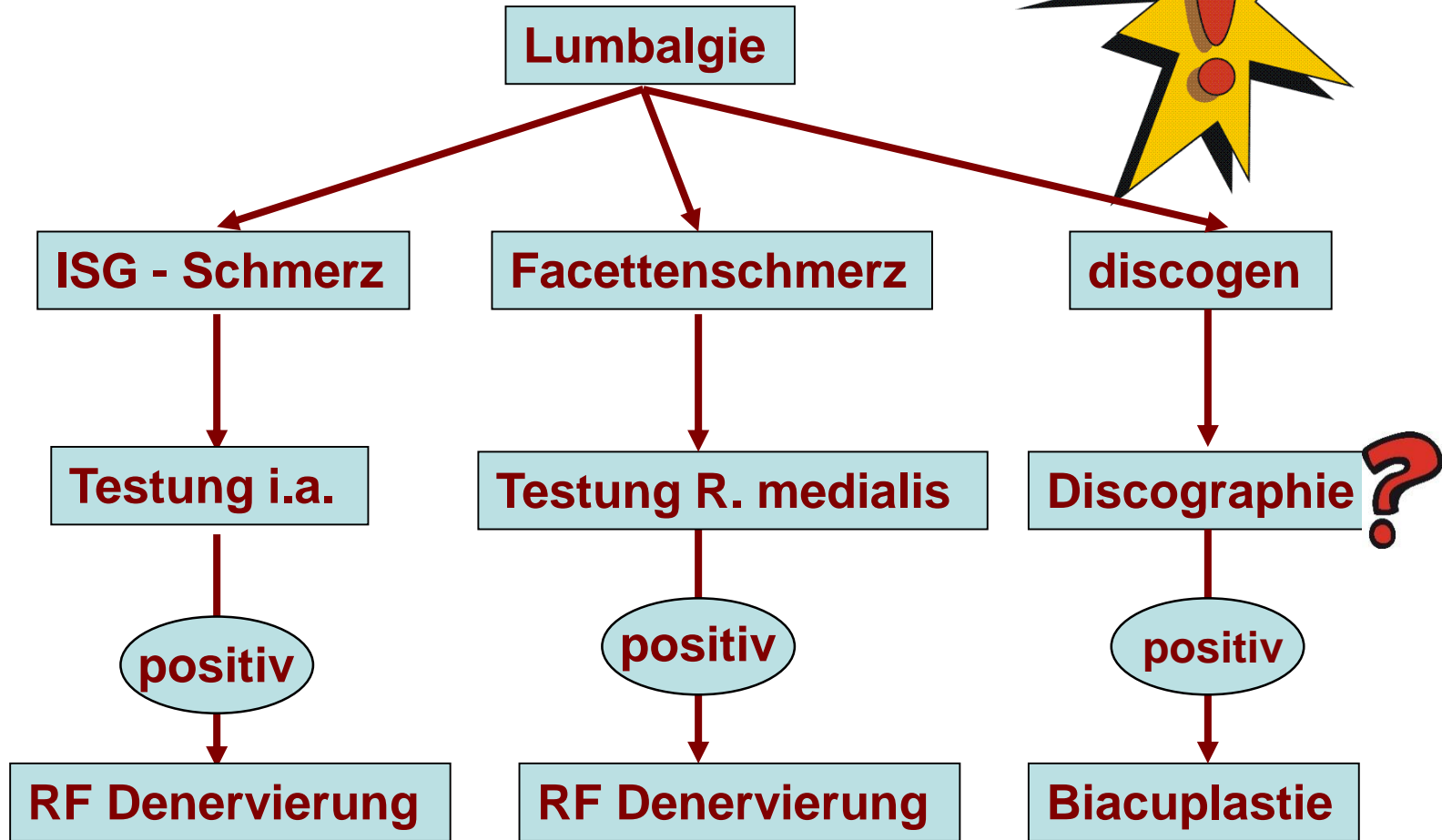

- Einführung
- ISG
- Facetten
- Discus
- Piriformis
- Take Home

Take Home Message



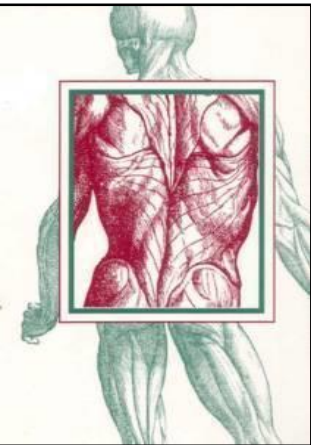

- Einführung
- ISG
- Facetten
- Discus
- Piriformis
- Take Home

Take Home Message



- Einführung
- ISG
- Facetten
- Discus
- Piriformis
- Take Home

Take Home Message



Einführung

ISG


Facetten

Discus

Piriformis

Take Home

Take Home Message



1. Facetten-, ISG- und discogener Schmerz und Triggerpunkte sind „spezifisch“ !

Einführung

ISG


Facetten

Discus

Piriformis

Take Home

Take Home Message



- 1. Facetten-, ISG- und discogener Schmerz und Triggerpunkte sind „spezifisch“ !**
- 2. Ohne klinische Untersuchung keine Diagnose**

Einführung

ISG


Facetten

Discus

Piriformis

Take Home

Take Home Message



- 1. Facetten-, ISG- und discogener Schmerz und Triggerpunkte sind „spezifisch“ !**
- 2. Ohne klinische Untersuchung keine Diagnose**
- 3. Ohne „Testung“ keine Intervention**

Einführung

ISG


Facetten

Discus

Piriformis

Take Home

Take Home Message



- 1. Facetten-, ISG- und discogener Schmerz und Triggerpunkte sind „spezifisch“ !**
- 2. Ohne klinische Untersuchung keine Diagnose**
- 3. Ohne „Testung“ keine Intervention**
- 4. Physiotherapie wichtigster Partner**

Einführung

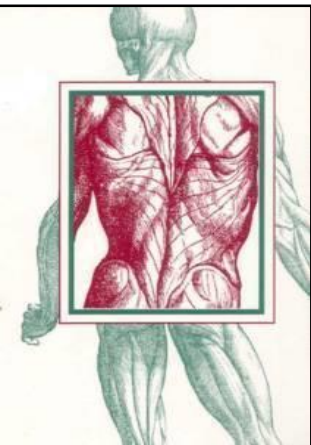
ISG

Facetten

Discus

Piriformis

Take Home



Danke für Eure Aufmerksamkeit !



Einführung

ISG

Facetten

Discus

Piriformis

Take Home

ordination@ortho-machacek.at